

## Rectal leiomyoma, a rare entity

Tagore Sunkara,<sup>1</sup> Eric Omar Then,<sup>2</sup>  
Andrea Culliford,<sup>2</sup> Vinaya Gaduputi<sup>2</sup>

<sup>1</sup>Division of Gastroenterology & Hepatology, The Brooklyn Hospital Center, Brooklyn, NY; <sup>2</sup>Department of Internal Medicine, SBH Health System, Bronx, NY, USA

### Abstract

Rectal tumors are often encountered as an incidental finding on screening colonoscopy. As per the World Health Organization, they are categorized according to their histologic appearance. These include epithelial tumors, mesenchymal tumors and lymphomas. Of interest, in our case, are mesenchymal tumors. These are sub-classified into leiomyomas and gastrointestinal stromal tumors. Our case is a 33-year old male who was diagnosed with a rectal leiomyoma. The uncommon incidence and subsequent management of a rectal leiomyoma in a male, make this case worthy for literature review.

### Introduction

Rectal leiomyomas have been reported as far back as 1872.<sup>1</sup> Since then, they have had an incidence rate of a mere 1 for every 2000 rectal tumors.<sup>2</sup> Risk factors for developing rectal tumors include smoking, immunosuppression, human papillomavirus, HIV infection and physical trauma, including receptive anal intercourse.<sup>3</sup> These factors are consistent with our case, because our patient is an HIV positive, homosexual male, with a history of receptive anal intercourse. Symptoms on presentation of rectal leiomyomas, mimic those of any other type of rectal tumor. These include dyschezia, rectal bleeding, and constipation.<sup>4</sup> Surgical resection has been long considered first-line therapy in management, but recently, endoscopic resection is challenging this consensus.

### Informed consent statement

Informed consent for participation was obtained from this patient.

### Case Report

A 33-year old man with past medical history of HIV (on retroviral therapy) with

undetectable viral load, anxiety disorder presented to the gastroenterology clinic for evaluation of intermittent diarrhea with hematochezia for about a month prior to presentation. Patient denied fevers, loss of appetite, early satiety, unintentional weight loss or recent antibiotic use. Laboratory studies revealed hemoglobin of 11.9 gm/dL and mean corpuscular volume (MCV) of 82. Stool work up was negative for white blood cells (WBC), ova and parasites and clostridium difficile toxin. Diagnostic colonoscopy was scheduled to evaluate infectious versus inflammatory colitis. Colonoscopy showed fair bowel preparation with patchy erythematous mucosa in the descending colon, non-bleeding small internal hemorrhoids on retroflexion and a 3 mm sessile polyp in the rectum (Figure 1) removed with excisional jumbo biopsy forceps. Pathology of the rectal polyp revealed fascicular pattern of smooth muscle bundles separated by connective tissue consistent with leiomyoma (Figure 2). An endoscopic ultrasound (EUS) was performed to ensure complete removal of the tumor. No residual leiomyomatous tissue was seen on EUS (Figure 3). Informed consent for participation was obtained from this patient.

### Discussion and Conclusions

Leiomyomas are by definition benign tumors of smooth muscle. As such, they can theoretically develop wherever smooth muscle is found. Because of this, their presentation, type and location may vary greatly between cases. Gender predilection most often favors females. They are commonly found in the uterus and are referred to as uterine fibroids. Less frequently they are located outside of the uterus, with reported sites including the esophagus, small bowel, urinary bladder, gallbladder and skin.<sup>5</sup> Even more rare are extra-uterine leiomyomas presenting in males. In our case we have an extra-uterine leiomyoma presenting in the rectum of a 33-year old male.

Overall, leiomyomas comprise about 0.03 to 0.05% of all rectal tumors.<sup>6</sup> While they are more common in women, there is data showing that leiomyomas of the gastrointestinal tract are more prevalent in males. A study done in 2001 evaluated a total of 88 patients in two institutions with confirmed leiomyoma of the rectum or colon. Their results showed a significant male predominance in both institutions. Ratios of male to female were 2.6:1 and 2.4:1.<sup>7</sup>

Clinical manifestations of rectal leiomyoma include intestinal obstruction, hemorrhage and perforation into the peri-

Correspondence: Tagore Sunkara, Division of Gastroenterology & Hepatology, The Brooklyn Hospital Center, Clinical Affiliate of The Mount Sinai Hospital, 121 DeKalb Avenue, Brooklyn, NY 11201, USA.  
Tel.: +1.217.671.2094 - Fax: +1.718.250.8120.  
E-mail: tagoresunkara@hotmail.com

Key words: Leiomyoma; fibromyoma; rectal tumor; diarrhea; hematochezia.

Contributions: TS, VG, conception and design; TS, EOT, VG, analysis and interpretation; TS, EOT, AC, VG, article drafting and critical revision, final approval of the article.

Conflict of interest: the authors declare no conflict of interest.

Received for publication: 15 December 2017.  
Revision received: 29 January 2018.  
Accepted for publication: 26 February 2018.

This work is licensed under a Creative Commons Attribution NonCommercial 4.0 License (CC BY-NC 4.0).

©Copyright T. Sunkara et al., 2018  
Licensee PAGEPress, Italy  
Clinics and Practice 2018; 8:1053  
doi:10.4081/cp.2018.1053

toneal cavity.<sup>8</sup> The severity of each manifestation depends greatly on how early these tumors are detected. Diagnostic modalities include colonoscopy, endoscopic ultrasound (EUS), computed tomography and magnetic resonance of the rectum.<sup>6</sup> After screening with colonoscopy, EUS is uniformly preferred over the aforementioned modalities. A cohort of 80 patients diagnosed with rectal cancer, showed that EUS was more accurate than CT in staging rectal carcinomas.<sup>9</sup> This impacts management because the treatment of rectal leiomyoma differs with depth of invasion. Ultimately, to make a definitive diagnosis, biopsy is required.

Histologically, leiomyomas are characterized by patterns of whorled smooth muscle bundles separated by connective tissue.<sup>10</sup> The individual smooth muscle cells are described as spindle-like (elongated), with eosinophilic or occasional fibrillar cytoplasm and distinct cell membranes. It is important to make the distinction between leiomyomas and gastro-intestinal stromal tumors (GIST). Microscopically, GIST tumors also have spindle cells with eosinophilic fibrillar cytoplasm. To set them apart, special staining is required. A GIST will stain positive for c-kit (CD117), however a leiomyoma will stain positive for actin or desmin.<sup>11</sup>

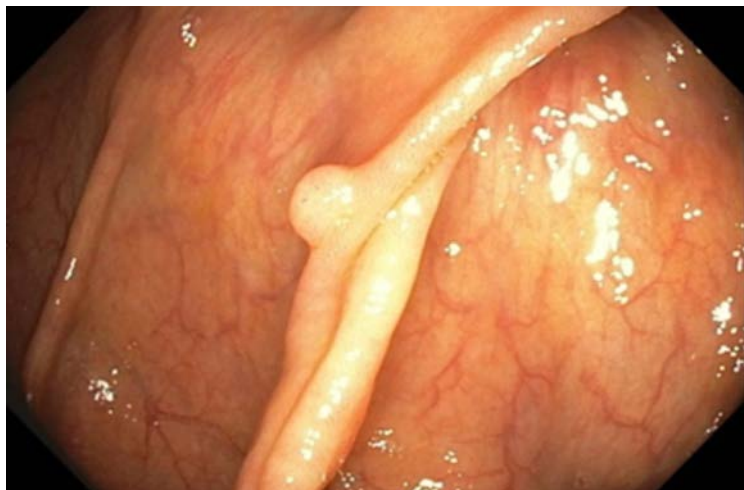

Figure 1. Colonoscopy showing a sessile 3 mm polyp in the rectum.

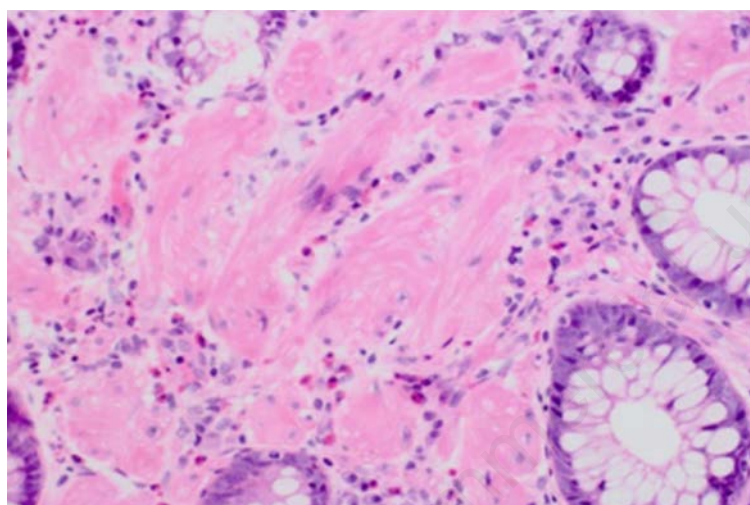


Figure 2. Histology of rectal polyp (magnification: 40x) showing fascicular pattern of smooth muscle bundles separated by connective tissue consistent with leiomyoma.

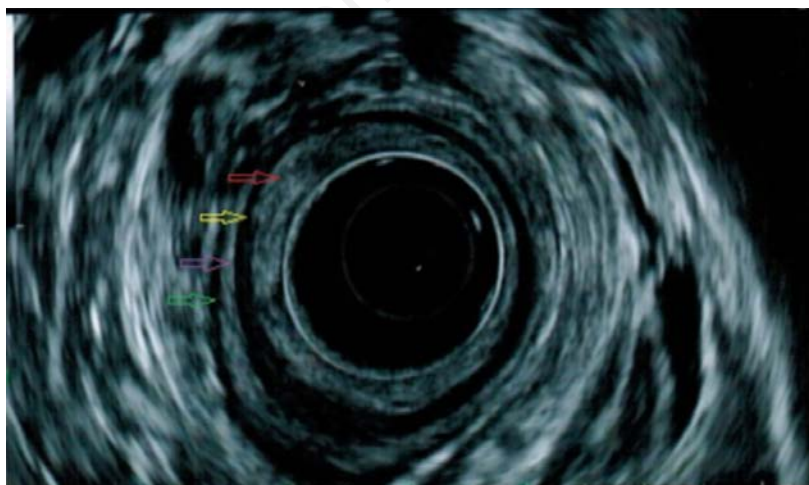


Figure 3. Endoscopic ultrasound (EUS) performed after the endoscopic resection of the leiomyoma revealing no residual lesion in the rectum. Mucosa (red arrow), Muscularis mucosae (yellow arrow), Submucosa (purple arrow) and Muscularis propria (green arrow).

It is also important to make the distinction between leiomyomas, and their malignant counterpart leiomyosarcomas. Both of these entities have identical histology with divergent prognoses. The latter of the two possesses a poor prognosis, with survival rates ranging from 20-40% at 5 years.<sup>12</sup> In contrast, rectal leiomyomas have been demonstrated to rarely show recurrence, and death is mostly attributed to other causes.<sup>7</sup> With regards to diagnosis, obtaining an adequate tissue sample is essential in identifying leiomyosarcomas. These would show large tumor cells, few stromal fibers, nuclear pleomorphism and increased mitotic activity.<sup>12</sup> Oftentimes superficial samples have been incorrectly diagnosed as benign.<sup>13</sup> This underscores the importance of tumor resection, both for accurate identification, and for adequate treatment.

As mentioned before, treatment of a rectal leiomyoma differs with depth of invasion. Surgical resection is generally considered the gold standard for tumors found deep within the submucosa. If the tumor originates from the muscularis mucosae, above the submucosal layer, it can be safely removed using endoscopic resection.<sup>11</sup> Endoscopic resection of submucosal tumors can be accomplished in multiple ways. A widely used method that has proven to be successful is resection with an electro-surgical snare. Prior to resection, the submucosal layer beneath the lesion is injected with dye (methylene blue). This is done to create a visible division between the submucosal layer, and tumor tissue, allowing for more precise resection.<sup>14</sup> A second method that is also effective is known as the bite on bite excisional biopsy. This method consists of taking multiple biopsies (bites), one on top of the other, until full resection is accomplished.<sup>15</sup> When attempting an excisional biopsy, it is important to use jumbo forceps due to the large surface area it provides.<sup>16</sup> In our case, tumor resection was achieved with excisional biopsy using jumbo forceps. Endoscopic resection is preferable to surgery due to its cost-effectiveness and decreased risks of perioperative complications.

## References

1. Serra J, Ruiz M, Lloveras B, et al. Surgical outlook regarding leiomyoma of the rectum. Report of three cases. *Dis Colon Rectum* 1989;32:884-7.
2. Kusminsky RE, Bailey W. Leiomyomas of the rectum and anal canal: report of six cases and review of the literature. *Dis Colon Rectum* 1977;20:580-99.
3. Ryan DP, Comptom CC, Mayer RJ.

- Carcinoma of the anal canal. *N Engl J Med* 2000;342:792-800.
4. Sasaki K, Gotoh Y, Nakayama Y, et al. Leiomyoma of the rectum. *Int Surg* 1985;70:149-52.
  5. Fasih N, Prasad Shanbhogue AK, Macdonald DB, et al. Leiomyomas beyond the uterus: unusual locations, rare manifestations. *Radiographics* 2008;28:1931-48.
  6. Silvia RDP, Saad-Hoossne R, Ferraz RA, et al. Treatment of rectal leiomyoma by endoscopic resection. *J Coloproctol* 2011;31:382-6.
  7. Miettinen M, Sarlomo-Rikala M, Sobin LH. Mesenchymal tumors of muscularis mucosae of colon and rectum are benign leiomyomas that should be separated from gastrointestinal stromal tumors - a clinicopathologic and immunohistochemical study of eighty-eight cases. *Mod Pathol* 2001;14:950-6.
  8. De Palma GD, Rega M, Masone S, et al. Lower gastrointestinal bleeding secondary to a rectal leiomyoma. *World J Gastroenterol* 2009;15:1769-70.
  9. Siddiqui AA, Fayiga Y, Huerta S. The role of endoscopic ultrasound in the evaluation of rectal cancer. *Int Semin Surg Oncol* 2006;3:36.
  10. Manxhuka-Kerliu, Kerliu-Saliu I, Sahatciu-Meka V, et al. Atypical uterine leiomyoma: a case report and review of the literature. *J Med Case Rep* 2016;10:22.
  11. Lee SH, Huh GY, Cheong YS. A case of endoscopic resection of a colonic semipedunculated leiomyoma. *J Korean Soc Coloproctol* 2011;27:215-9.
  12. Ouh YT, Hong JH, Min KJ, et al. Leiomyosarcoma of the rectum mimicking primary ovarian carcinoma: a case report. *J Ovarian Res* 2013;6:27.
  13. Sahli N, Khmou M, Khalil J, et al. Unusual evolution of leiomyosarcoma of the rectum: a case report and review of the literature. *J Med Case Rep* 2016;10:249.
  14. Ishiguro A, Uno Y, Ishiguro Y, Munakata A. Endoscopic removal of rectal leiomyoma: case report. *Gastrointest Endosc* 1999;50:433-6.
  15. Ji JS, Lee BI, Choi KY, et al. Diagnostic yield of tissue sampling using a bite-on-bite technique for incidental subepithelial lesions. *Korean J Intern Med*. 2009;24:101-5.
  16. Elmunzer BJ, Higgins PD, Kwon YM, et al. Jumbo forceps are superior to standard large-capacity forceps in obtaining diagnostically adequate inflammatory bowel disease surveillance biopsy specimens. *Gastrointest Endosc* 2008;68:273-8.