

Submandibular sialolithiasis: A series of three case reports with review of literature

Sandeep Pachisia, Gaurav Mandal, Sudipto Sahu, Sucharu Ghosh

Department of Oral and Maxillofacial Surgery, Haldia Institute of Dental Sciences and Research, West Bengal University of Health Sciences, Haldia, West Bengal, India

Abstract

One of the most common disorders of the salivary glands is sialolithiasis. A history of pain or/and swelling in the salivary glands, especially during meal suggests this diagnosis. For small and accessible stones conservative therapies like milking of ducts with palliative therapy can produce satisfactory results. Surgical management should be considered when the stone/stones are inaccessible or large in size as conservative therapies turned out to be unsatisfactory. In this paper, we present three cases of sialolithiasis in the submandibular gland along with a review of existing literature. The purpose of this paper is to add three more cases to the literature and review the theories of etiology, clinical features, available diagnostic and treatment procedures.

Introduction

Sialolithiasis is considered to be the most common salivary gland disorder and it accounts for about 1.2% of unilateral major salivary gland swellings. Submandibular gland has the highest predilection for sialolithiasis with 80% occurrence rate, followed by the parotid (19%) and the sublingual (1%) glands. Sialolithiasis is usually seen between the age of 30 and 60 years. It is uncommon in children as only 3% of all sialolithiasis cases has been reported in the pediatric population. Males are affected twice as much as females.

The clinical symptoms include swelling and pain in the affected gland. If the blockage of the duct is complete, the symptoms will be severe. Pain and swelling, may be recurrent and most pronounced during meals. In this paper we present three cases of large (>8mm) sialoliths of the submandibular gland, treated with transoral sialolithotomy and a review of existing literature, emphasizing on the theories of eti-

ology, usual and unusual locations, clinical features, diagnostic and treatment modalities, along with their indications and contraindications.

Case Reports

Case #1

A 40-year-old male patient reported to our institute with a chief complaint of recurrent episodes of pain, difficulty in swallowing and swelling in the neck (Figure 1A), for the last 2-3 years. The last episode occurred 1-2 months prior to the visit and the pain has been persistent since.

On extraoral examination, a diffuse swelling over the left submandibular region was found. On bimanual palpation left submandibular gland was firm and tender and a single tender left submandibular lymph node was palpated.

Intraorally left submandibular duct opening was inflamed and erythematous along with a diffuse swelling and discharge of pus (Figure 1B). The swelling was firm to hard on palpation, running from 1 cm posterior to the ductal opening to the base of the tongue posteriorly. Also, mild elevation of the tongue was seen.

The mandibular occlusal radiograph revealed a single ovoid radiopacity extending from 36 tooth to the distal aspect 37 tooth (Figure 1C). On the basis of clinical and radiological findings, we diagnosed the case as a left submandibular sialolithiasis.

All preoperative investigations were under normal limits and the patient was under antibiotic coverage. Under local anesthesia, an intraoral incision was made in the floor of the mouth. The duct was opened and the sialolith was removed in a single piece. It was 1.5 cm in length and 1 cm in diameter. It weighed 0.07g on an electronic weighing machine. Sutures were placed to close the area (Figure 1D).

Case #2

A 26-year-old male patient reported with swelling below the tongue, which was associated with pain for 1 week (Figure 2A).

Clinical examination revealed a superficial, 5 mm hard swelling situated near the lingual frenum, which was extremely tender on palpation. There was no associated discharge or bleeding reported from the area (Figure 2B). The mandibular occlusal radiograph revealed a radiopacity extending from the lateral incisor to the second premolar area (Figure 2C).

Under local anesthesia, an incision was made at the ductal orifice and calculi was

Correspondence: Sucharu Ghosh, Department of Oral and Maxillofacial Surgery, Haldia Institute of Dental Sciences and Research, West Bengal University of Health Sciences, Haldia, West Bengal, India.
Tel.: +919062792661.
E-mail: sucharu@outlook.com

Key words: Sialolithiasis; Submandibular gland; Sialolithotomy.

Contributions: the authors contributed equally.

Conflict of interest: the authors declare no potential conflict of interest.

Funding: none.

Received for publication: 28 November 2018.

Revision received: 20 February 2019.

Accepted for publication: 20 February 2019.

This work is licensed under a Creative Commons Attribution NonCommercial 4.0 License (CC BY-NC 4.0).

©Copyright S. Pachisia et al., 2019
Licensee PAGEPress, Italy
Clinics and Practice 2019; 9:1119
doi:10.4081/cp.2019.1119

exposed and retrieved. The sialolith was about 5×8.5mm in size and weighted only 0.03g. Sutures were placed to close the surgical area (Figure 2D).

Case #3

A 75-year-old man visited us with a chief complaint of swelling and pain during swallowing on the right side of the face (Figure 3A).

Extraoral examination revealed no facial asymmetry but firm and tender right submandibular lymph nodes. Intraoral examination showed mild elevation of the tongue with swelling and the stone was visible at the right Wharton's duct opening (Figure 3B). A diffuse swelling was palpable on the floor of the mouth on the right side of the lingual frenum. On the basis of the above findings, we came to a provisional diagnosis of right submandibular sialolithiasis. A diffused radiopacity was seen from the mesial surface of the first molar to the distal surface of the second molar in the mandibular occlusal radiograph, which confirmed our diagnosis (Figure 3C).

Sialolithotomy was done under local anesthesia and sutures were placed (Figure 3D). The retrieved sialolith was approximately 1×3cm in size and weighted almost 0.1g. Post-operative healing was smooth and uneventful.

Discussion

Sialoliths are condensations of calcium salt primarily calcium phosphate in the form of hydroxyapatite with small amounts of magnesium carbonate and ammonium. Wakely reported the distribution of sialoliths: 64% in submandibular gland and duct, 20 % in the parotid gland and duct and 16% in the sublingual gland and duct.

Most of the sialolith are usually of 5 mm in maximum diameter and all the stones over 10 mm should be reported as a sialolith of unusual size. Furthermore, they are classified as *giant* in case any dimension exceeds 15 mm. One of the largest sialoliths of 72 mm size was reported by Rai and Burman.¹ All the stones found by us were between 8.5mm to 30mm size, the third case had the highest and the second case had the lowest dimensions.

Males are affected twice as much as females. All our cases were in male patients which supports the data found by most other studies. While Seldin *et al.*² and Lustmann *et al.*³ found the M:F ratio to be 1:1 in their studies.

Etiology

Though definite etiology is still ambiguous, sialoliths are thought to occur as a result of deposition of mineral salts around an initial nidus consisting of salivary mucin, bacteria or desquamated epithelial cells. They form as a result of mineralization of debris that has accumulated in the lumen of the duct. This debris includes bacterial colonies, exfoliated ductal epithelial cells, mucus plugs, foreign bodies or other cellular debris. Factors like stagnation of salivary flow, dehydration, and change in salivary pH associated with oropharyngeal sepsis, impaired crystalloid solubility, high alkalinity, and increased calcium content, and physical trauma to salivary duct or gland may predispose to calculus formation. The definite etiology of our cases still remains unknown.

Two stages of sialolith formation can be found in the literature: i) central core formation and ii) layered periphery formation.⁴ Firstly, mineral salts bound by certain organic substances precipitate to form the central core. Then, in the second phase, some organic and inorganic materials deposit around the central core in layers. Parotid and submandibular stones are thought to frequently form around a nidus of inflammatory cells or foreign body and a nidus of mucous respectively. Boynton and Lieblch in 2014 reported an unusual case in which a facial hair of the patient got entrapped in the Wharton's duct and acted

as a nidus for the formation of a sialolith.⁵ Another theory has proposed that an unknown metabolic phenomenon can lead to precipitation of salivary calcium and phosphate ions by increasing the salivary bicarbonate content, which in turn alters the calcium phosphate solubility.

A retrograde theory suggested that any substance or bacteria of the oral cavity, that had migrated into the salivary ducts, can act as a nidus for further calcification.⁴ Marchal *et al.*⁴ further suggested that easier retrograde migration of materials can occur due to variation in the sphincter-like mechanism in the first 3 cm of the Wharton's duct.

Recently, Sherman and McGurk⁶ the incidence of salivary calculi is not significantly associated with water hardness.

Long-standing obstruction by a sialolith may severely damage the acini of the gland, resulting in a permanent decrease, or even absence of salivary secretion. This reduced or absent salivary secretion may give rise to recurrent infections, which can lead to atrophy of the gland with loss of secretory function and ultimately fibrosis.

Location

Salivary calculi related to the submandibular gland are more common than the parotid gland due to some factors like the direction of salivary flow against gravity, a longer and more tortuous structure of Wharton duct and the higher calcium and mucin content of saliva produced in the submandibular gland.⁷ Calculi are more often found within the Wharton's duct, than at the hilum of the duct or inside the gland. According to Pizzirani *et al.*,⁸ they are more frequently found in the left submandibular gland as in our case. However, few studies reported a higher incidence in the right site. Locations of the stones found in our cases are listed in Table 1.

Sialoliths usually remain within the gland and enlarge but they rarely migrate to other locations; Drage *et al.*⁷ reported three cases of migratory sialoliths in 2005. Sialoliths of submandibular gland detected in the oral cavity or fistulized to neck have been reported in the literature. Koo *et al.* reported two cases of sialolithiasis within the ipsilateral remaining Wharton's duct in

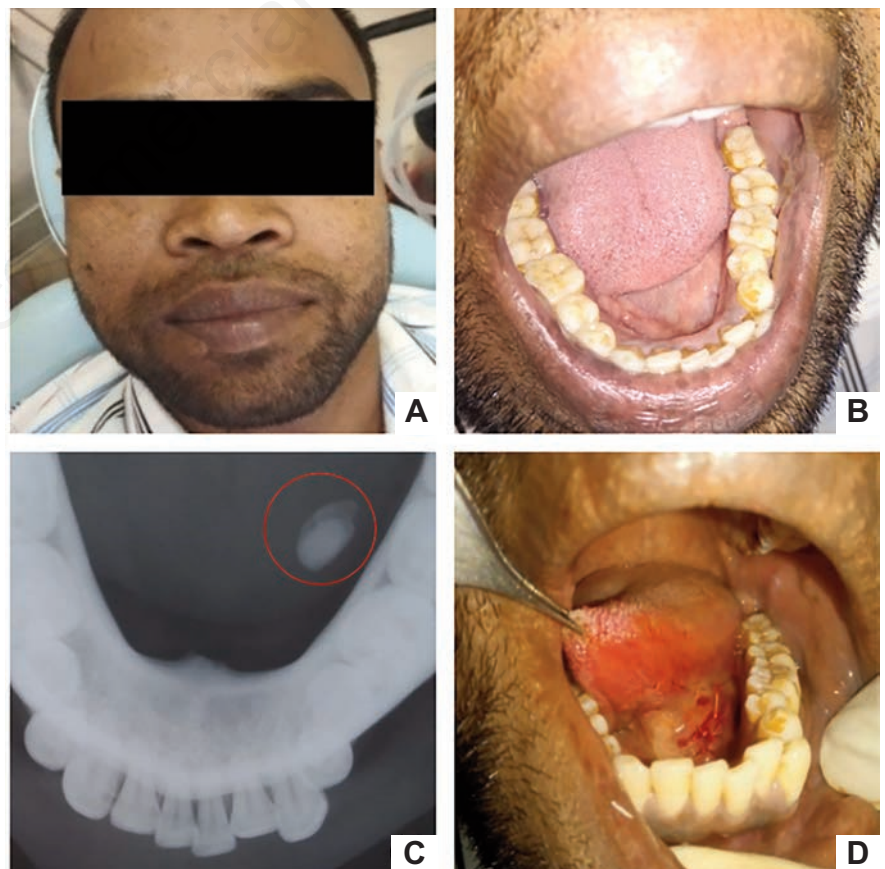


Figure 1. (A) Patient's profile; (B) swelling in floor of the mouth; (C) mandibular occlusal radiograph showing sialolith in the submandibular region; (D) sialolithotomy and suturing of the defect.

patients with isolated aplasia of a unilateral submandibular gland.⁹

Clinical features

Submandibular gland sialolithiasis is generally asymptomatic in nature. The symptoms include pain and swelling of the involved gland caused by the accumulation of saliva due to blockage of the lumen of Wharton's duct by a salivary calculus. Recurrent infections may occur due to the ascent of bacteria into the parenchyma of the gland. All our patients suffered from pain and infection for 1 week to as long as 2-3 years.

Diagnosis

Sialoliths are traditionally diagnosed by clinical features coupled with radiographs, though newer more sophisticated techniques are now available.

Investigation and palpation

The diagnosis of salivary calculi is based on the patient's history and clinical examination which are supplemented by radiographic findings. The patient may present with pain and swelling of the concerned gland at meal times and in response to other salivary stimuli, pus may be seen draining from the duct and signs of systemic infection. Siddiqui found that small and sometimes even large sialoliths can be asymptomatic.

A posterior to anterior bimanual palpation of the floor of the mouth reveals submandibular stones in a large number of cases. As all our stones were inside the Wharton's duct, they were palpable on the floor of the mouth. Intraoral palpation around Stenson's duct orifice may reveal a parotid stone, though deeper stones are often not palpable. When minor salivary glands are involved, they are usually in the buccal mucosa or upper lip, forming a firm nodule that may mimic tumor. In all our cases, a diffuse hard swelling was found on the floor of the mouth of the affected side and the first and third cases were associated with pus discharge.

Radiograph

When no stone can be seen or palpated, imaging studies can be a great help in diagnosing sialolithiasis. Occlusal radiographs are extremely useful in showing radiopaque stones unless otherwise there are radiolucent stones.

Submandibular gland calculi are mostly radiopaque (80% to 94.7%). According to Williams, standard extraoral radiographs are less diagnostic than intraoral radiographs or occlusal views. Stones in the

superior gland or proximal Wharton's duct may get superimposed on the teeth or mandible, which can make visualization difficult in extraoral radiographs. In the study of Lustmann *et al.*, intraoral radiographs detected 94.7% of the cases. However, in extraoral radiographs stones were superimposed on bony structures and teeth so, their identification was difficult, especially when they were small.² Supporting this, intraoral mandibular occlusal radiographs precisely revealed all

our stones. It is very rare to find a patient with both radiopaque and radiolucent stones. So, finding one radiopaque stone is enough to rule out the possibility of finding any additional radiolucent stones. Other calcifications in the area, which may confuse the diagnoses, are: i) phleboliths or calcifications of intravascular thrombi either in a hemangioma or in the lingual veins; ii) calcified cervical lymphadenopathy, which may have occurred in relation to tuberculous infection; iii) arterial atherosclerosis of

Table 1. Details of the sialoliths.

	Case report #1	Case report #2	Case report #3
Sex	Male	Male	Male
Age (years)	40	25	75
Gland involved	Submandibular	Submandibular	Submandibular
Side involved	Left	Left	Right
Location of the sialolith	Inside the canal	In the canal orifice	Inside the canal
Size of the sialolith	1.5×0.5 cm	5×8.5mm	1×3cm
Weight (in grams)	0.05g	0.01g	0.1g

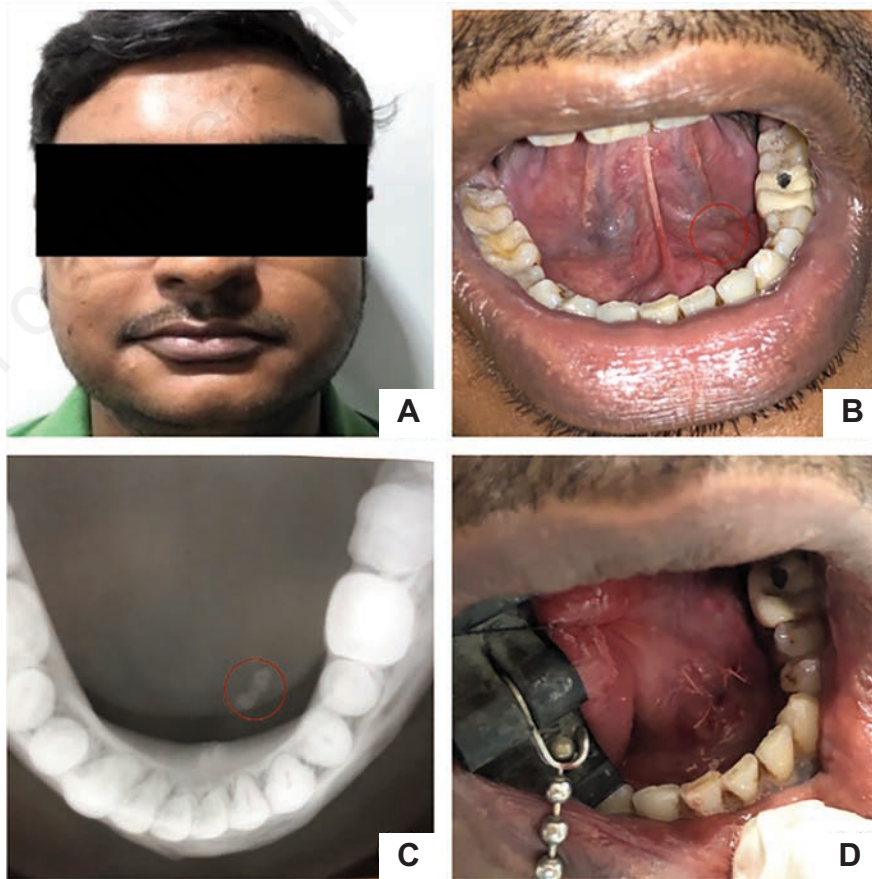


Figure 2. (A) Patient profile; (B) intraoral swelling in submandibular region; (C) mandibular occlusal radiograph showing sialolith in the submandibular region; (D) sialolithotomy and suturing of the defect.

the lingual artery demonstrating calcifications along the floor of mouth.

Sialography

Sialography, which was previously used widely for detection of duct stricture, stenosis or sialoliths, is a method of injecting contrast material into Stenson's or Wharton's duct for visualization.

Sialographic studies may reveal features of the involved salivary glands, having important diagnostic value. The anatomy of the duct can be displayed, revealing its form as narrow or large, the presence of secondary branches leaving the main duct, and the presence of accessory glands or sialolithiasis, including their dimensions, number, and positions. Sialography is a very helpful tool in cases when signs of sialadenitis are related to a radiolucent or deeply impacted submandibular/parotid stone. Sialography was chosen over the other tools by Katz,¹⁰ Hasson and Nahlieli,¹¹ for salivary gland assessment. On the other hand, Marchal and Dulguerov¹² have said that there is always a risk of pushing the sialoliths deeper into the duct while injecting the contrast media, which may further complicate their removal. This was supported by Varghese *et al.*,¹³ who claimed that the major disadvantage of sialography is its invasiveness. They studied 49 patients and concluded that magnetic resonance sialography is more sensitive to tight strictures when compared to conventional sialography but not when salivary stones are present.

Patients with acute infection and contrast allergy is an absolute contradiction of sialography.⁴

Sialendoscopy

Introduction of sialendoscope has taken the diagnosis of these pathologies to the next level. Katz and Fritsch,¹⁰ used a flexible endoscope for the first time in the 1990s for evaluation of the salivary gland ducts. Sialendoscopy was upgraded through the ages by the advancements in technology resulting in enhancement of optical resolution and miniaturization of the instruments. In addition to the radiolucent stones and those not shown in the imaging techniques, any possible duct stricture or other kinds of obstructions can also be found with this technique. In the case of a small sialolith and favorable conditions, a definitive sialolithotomy can be performed with sialendoscopy. Kondo *et al.* recently proved its diagnostic value in patients with swelling of the parotid gland when sialoliths are undetected with computed tomography.¹⁴

Duct perforation is the most usual and common complication of the procedure,

which leads to fluid extravasation in the floor of the mouth. Temporary injury of the lingual nerve has been also reported in the literature.

Ultrasonography

Katz *et al.* and various other authors have reported that ultrasonography is a very useful diagnostic tool for submandibular sialolithiasis with a sensitivity and specificity between 90% and 95% respectively.¹⁵ However, a major drawback of this procedure is that smaller calculi (>2mm) remain undetected most of the times.

Newer techniques

Newer techniques such as Computed tomography (CT) and Magnetic resonance imaging (MRI) have revolutionized the diagnostic aspect of sialolithiasis.

Computed tomography is very helpful in cases where other techniques provide ambiguous results, especially in parotid duct calculi. An associated abscess or ranula can be easily detected by CT scan in conjunction with soft tissue and bone algorithm.

Usually, a CT scan is done both with or without contrast enhancement to differentiate between calculi and vascular structures.

Magnetic resonance imaging is another very helpful tool for the identification of smaller stones and to differentiate acute from chronic obstruction. Sialo-Magnetic Resonance Imaging is a non-invasive method of diagnosing sialoliths. It does not use any contrast vehicle and ionizing radiation overcoming, the major disadvantages of both computed tomography and contrast sialography. Acute inflammation is not a contradiction to this technique, which is a great advantage. The detailed morphology of the salivary ducts, up to second and third order branches can be seen with this technique, without the need for duct cannulation.

Management

Preservation of gland function in conjunction with low-level risk and discomfort for the patient should be the primary objective in the treatment of sialolithiasis. The treatment of choice varies according to the size, location and the number of stones.

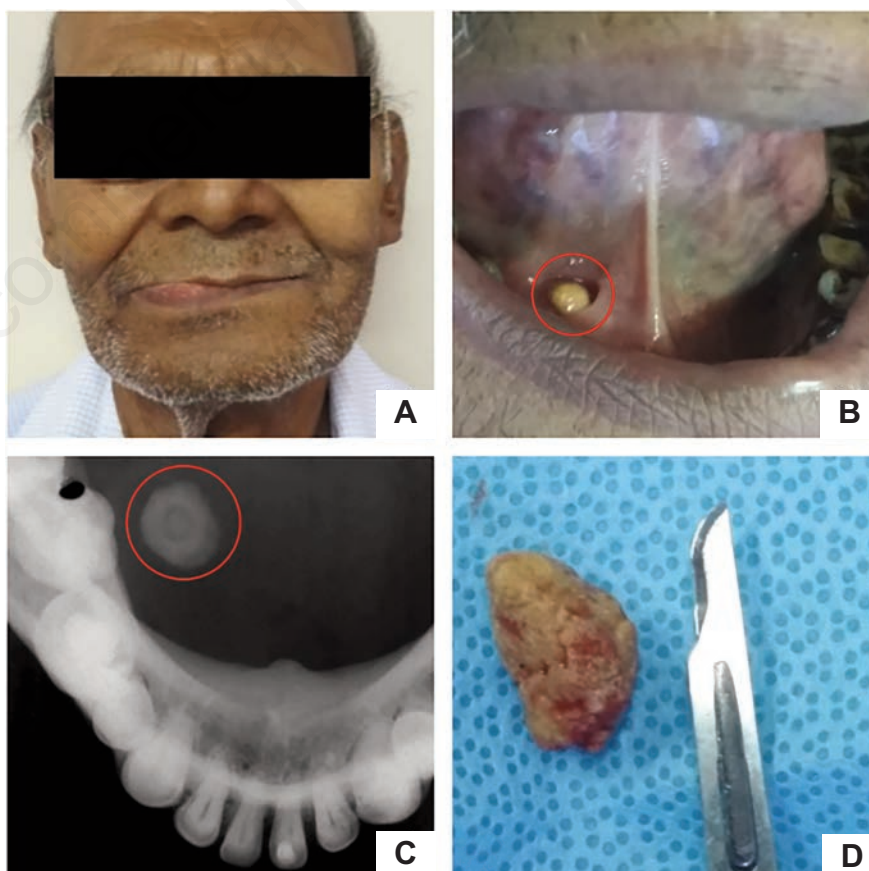


Figure 3. (A) Patient profile showing no facial asymmetry; (B) sialolith protruding out of the duct orifice; (C) mandibular occlusal radiograph showing sialolith in the second molar region; (D) excised sialolith.

Conservative management

When stones are small, moist warm heat application with the administration of sialogogues and gland massage help in flushing the stone out of the duct. Small sialoliths can be removed through the duct orifice using bimanual palpation. The infection should be treated with antibiotics and these cases should be combined with simple sialolithotomy when required.

Sialendoscopy

Sialendoscopy, which is a minimally invasive technique, was first introduced by Katz¹⁰ in 1991 and has since been developed by Marchael *et al.*¹⁶ and Nahlieli *et al.*¹⁷ There have been many reports on Sialendoscopic surgery for submandibular gland sialolithiasis which discussed the usage of sialendoscopy for the removal of sialoliths. Klein and Ardekian¹⁸ mentioned that sialoliths upto the range of 4-5mm of diameter are the ideal for sialendoscopic removal while it is a challenge for the surgeons to perform sialendoscopy of the sialoliths located deep within the hilum. There are speculations regarding the endoscopic approach since a general consensus is yet to arrive on either the maximum diameter of the stones that could be removed without fragmentation or whether impacted or hard stones could be managed effectively by endoscopy alone.¹⁹ The general indication for the approach is the combination of sialendoscopy with extra-corporeal lithotripsy (Storz SL1 Minilith) using Thullium laser (Revolix) for the fragmentation of Lithiasis between the range of 4 and 8mm.

Interventional sialendoscopy, particularly in procedures involving large stones or stenotic ducts did fail even in the hands of experienced surgeons (about 20% failure rate). Marchal devised a technique to preserve the glands by a procedure involving combined transoral Sialendoscopy and an external approach to the Sialoliths. While involving the combined open and Sialendoscopic approach, Marchal made sure to stress on the exploration of the remaining of Wharton's duct Sialendoscopically to rule out any remaining fragments.²⁰

The measurement of the minor axes of the sialoliths with a soft tissue CT scan was correlated with treatment outcome of sialendoscopy alone by Kondo *et al.*²¹ and the measurement of the major axis showed no correlation with outcomes of sialendoscopy alone.

Retrograde sialendoscopy, described by Potash and Hoffman,²² is a novel technique that is useful as an adjunct to standard submandibular gland resection in the manage-

ment of sialolithiasis as Gallo *et al.* found that nearly 40% of submandibular stones are distal.²³

Surgical techniques

Upon failure of non-invasive techniques mainly due to the size of the stones and their location, the Sialoliths are treated by open surgical approaches. These include transoral duct incision, purely external approaches, or a combination of approaches. An Endoscopy assisted trans-oral removal technique for larger or impacted stones can also be of utility.

Zenk *et al.* concluded in their study that transoral removal should be the treatment of choice in patients with submandibular stones that can be palpated bimanually and localized by ultrasound within the perihilar region of the gland.²⁴ The minimum diameter of our stones being 8.5mm and localizable by palpation and radiographs, we chose the intraoral submandibular duct approach over the other techniques. To minimize the risk of injury to the sublingual glands, Park *et al.* have described an approach which has an added advantage of accessing the hilum of the submandibular duct without full dissection of the duct.²⁵ The surgical landmark is assessed by the triangle formed by the posterior edge of the mylohyoid muscle, the lingual nerve (retracted medially) and the medial margin of the mandible.

General Anaesthesia is preferred when the stones are approached using the external open method or difficult intra-oral approaches when the stone is located at or proximal to the hilum of the submandibular duct. General Anaesthesia is also preferred for combined endoscopic/external approaches. In cases requiring a trans-cervical approach, a shoulder roll is generally used to hyperextend the neck slightly.

Although advances in sialoendoscopy and minimally invasive surgery have minimized the need for salivary gland excision, still there are some situations where excision is inevitable. This takes into account the inclusion of symptomatic or recurrent sialadenitis which is caused by multiple intraparenchymal stones or due to the presence of a very large stone, intraoperative complications of sialoendoscopy which requires gland removal, or inability in extracting the stone when minimally invasive procedures listed above are used and/or residual symptoms which are present despite the removal of stones such as recurrent inflammation. The excision of submandibular gland for chronic sialadenitis is more frequent and is secondary to lithiasis.

The CO2 laser enables bloodless surgery and a clear vision of the operating site.

Intervention can be carried out during acute stages without spreading of infection, and with minimal post-operative pain and edema.²

A number of complications are associated with an open surgical approach. The primary concern is Postoperative neurologic damage. A major cause of patient morbidity includes various other complications, including sialoceles, salivary fistula, facial scarring and Frey's Syndrome. There is a greater risk of facial palsy as in parotid or Stenons sialolithiasis, there are branches of the facial nerve that cross over the duct. There might be instances of nonclosure of the duct because of an external incision, which might lead to salivary fistula.

Extracorporeal and Endoscopic Intracorporeal Shockwave Lithotripsy:

There have been alternative techniques that have been found out which includes the usage of Extracorporeal Shock Wave Lithotripsy and the most recent being using Endoscopic Intracorporeal Shock Wave Lithotripsy, where direct shockwaves are delivered to the surface of the stone lodgment inside the duct without damaging adjacent tissue (piezoelectric principle). A better option than surgical removal of the affected gland is Salivary Lithotripsy which is more useful and beneficial, as this prevents the risks of General Anaesthesia, Damage of the facial nerve, surgical scar, Frey's syndrome, and a minimum of discomfort to the patient, but also with the preservation of the gland.

Conclusions

Sialoliths should be always considered in submandibular and facial pain particularly when it is related to mealtime. A careful history and correct imaging techniques are required to confirm the clinical diagnosis and to define the precise location of the calcification.

Though advanced and more efficient methods are available occlusal radiographs are still useful in diagnosing sialoliths. Small stones can be treated conservatively but for larger stones, sialolithotomy combined with antibiotics is the treatment of choice if newer technologies are not available. According to literature, the success rate of the intraoral submandibular duct approach is between 85% and 100%.^{24,25} This submandibular duct technique is simple, adaptable to different anatomic situations and, can be performed under local anesthesia. Immediate and permanent post-surgery complications, such as lingual nerve injury, are exceptional.

References

1. Rai M, Burman R. Giant submandibular sialolith of remarkable size in the comma area of Wharton's duct: a case report. *J Oral Maxillofac Surg* 2009;67:1329-32.
2. Seldin HM, Seldin SD, Rakower W. Conservative surgery for the removal of salivary calculi. *Oral Surg* 1953;6:579-87.
3. Lustmann J, Regev E, Melamed Y. Sialolithiasis: A survey on 245 patients and a review of the literature. *Int J Oral Maxillofac Surg* 1990;19:135-8.
4. Marchal F, Kurt AM, Dulguerov P, Lehmann W. Retrograde theory in sialolithiasis formation. *Arch Otolaryngol Head Neck Surg* 2001;127:66-8.
5. Boynton TT, Lieblich SE. Unusual case of a sialolith: a case report. *Oral Surg Oral Med Oral Pathol Oral Radiol* 2014;117:e9-e10.
6. Sherman JA, McGurk M. Lack of correlation between water hardness and salivary calculi in England. *Br J Oral Maxillofac Surg* 2000;38:50-3.
7. Drage NA, Brown JE, Makdissi J, Townend J. Migrating salivary stones: report of three cases. *Br J Oral Maxillofac Surg* 2005;43:180-2.
8. Pizzirani C, Capuano A, Gemesio B, Simondi R. [Clinical-statistical considerations on 102 cases of salivary calculi]. *Mondo Odontostomatol* 1985;27:41-51.
9. Koo BS, Lee SW, Lee YM, et al. Sialolithiasis in a stump of Wharton's duct of an aplastic unilateral submandibular gland. *Int J Oral Maxillofac Surg* 2009;38:91-7.
10. Katz P, Fritsch MH. Salivary stones: innovative techniques in diagnosis and treatment. *Curr Opin Otolaryngol Head Neck Surg* 2003;11:173-8.
11. Hasson O, Nahlieli O. Endoscopy of salivary glands (sialoendoscopy): A new technique for the removal of the sialolithiasis. *Rev Assoc Paul Dent* 1998;52:277.
12. Marchal F, Dulguerov P. Sialolithiasis management: The state of the art. *Arch Otolaryngol Head Neck Surg* 2003;129:951.
13. Varghese JC, Thorton F, Lucey BC, et al. A prospective comparative study of MR sialography and conventional sialography of salivary duct disease. *AJR Am J Roentgenol* 1999;173:1497.
14. Kondo N, Yoshihara T, Yamamura Y, et al. Diagnostic and treatment effects of sialendoscopy for patients with swelling of the parotid gland when sialoliths are undetected with computed tomography. *Auris Nasus Larynx* 2018;45:880-4.
15. Katz P, Hartl DM, Guerre A. Clinical ultrasound of the salivary glands. *Otolaryngol Clin North Am* 2009;42:973-1000.
16. Marchal F, Dulguerov P, Becker M, et al. Specificity of parotid sialendoscopy. *Laryngoscope* 2001;111:264-71.
17. Nahlieli O, Baruchin AM. Endoscopic technique for the diagnosis and treatment of obstructive salivary gland diseases. *J Oral Maxillofac Surg* 1999;57:1392-401.
18. Klein H, Ardekian L. The treatment of large sialoliths by sialendoscopic combined approach. *J Oral Maxillofac Surg* 2014;72:737-43.
19. Dabirmoghaddam P, Hosseinzadehnik R. Interventional sialendoscopy with endoscopic sialolith removal without fragmentation. *Indian J Otolaryngol Head Neck Surg* 2013;65:111-5.
20. Marchal F. A combined endoscopic and external approach for extraction of large stones with preservation of parotid and submandibular glands. *Laryngoscope* 2007;117:373-7.
21. Kondo N, Yoshihara T, Yamamura Y, et al. Treatment outcomes of sialendoscopy for submandibular gland sialolithiasis: The minor axis of the sialolith is a regulative factor for the removal of sialoliths in the hilum of the submandibular gland using sialendoscopy alone. *Auris Nasus Larynx* 2018;45:772-6.
22. Potash A, Hoffman HT. Retrograde sialendoscopy: a new technique for avoiding retained ductal stones. *Ann Otol Rhinol Laryngol* 2012;121:38-43.
23. Gallo O, Berloco P, Bruschini L. Sialadenectomy. In: McGurk M, Renehan AG, eds. *Controversies in the management of salivary gland disease*. Oxford, England: Oxford University Press; 2001. pp 297-303.
24. Zenk J, Constantinidis J, Al-Kadah B, Iro H. Transoral removal of submandibular stones. *Arch Otolaryngol Head Neck Surg* 2001;127:432-6.
25. Park HS, Pae SY, Kim KY, et al. Intraoral removal of stones in the proximal submandibular duct: Usefulness of a surgical landmark for the hilum. *Laryngoscope* 2013;123:934-7.