

Mandibular neurofibroma: Case report of a rare tumor

Ziad Sleiman,¹ Loubna Abboud,¹
Elie Mehanna,¹ Ramzi Mahmoud,¹
Elie Yaacoub,¹ Georges Ghanime^{2,3}

¹Division of Plastic and Reconstructive Surgery, Lebanese Hospital Geitaoui, University Medical Center, Lebanese University, Beirut; ²Chair, Department of Surgery, Faculty of Medicine, Lebanese University; ³Head Division, Plastic and Reconstructive Surgery, Lebanese University Hospital, Geitawi, Lebanon

Abstract

Neural tumors localized in jaw bone are relatively rare. This article presents a case of intraosseous neurofibroma of the mandible in a 37-year-old female patient. A review of clinical, radiographic, histological features and surgical management of the patient are discussed along with a review of the literature.

Introduction

Neurofibromas (NFs) of the mandible are rare, around 50 cases have been reported in the literature.¹ World Health Organization defines NF as a benign tumor of the peripheral nerve sheath phenotype with mixed cellular components, including schwann cells, perineural hybrid cells and intraneural fibroblasts.² NFs can occur as a single or multiple lesions associated with neurofibromatosis type 1, which is a systemic condition caused by a germline mutation in the NF1 gene, a tumor suppressor gene located at 17q11.2.² The term *solitary NF of the oral cavity* was first described by Bruce in 1954, few cases have been reported since.³ When solitary NFs occur in the mandible there is a predilection for females (the female-to-male ratio is 2:1) and they are most frequently localized in the posterior part of the mandible.⁴ The average age is 27.5 years old (range 14-45).⁵

Case Report

A 37-year-old female patient presented to the Division of Plastic and Reconstructive Surgery at the Lebanese Hospital Geitaoui, with a history of right

sided facial pain in the mandibular area, of 1 year duration, increasing in intensity, associated with right sided lower lip paresthesia. There was a familial history of neurofibromatosis from the paternal side and a personal history of multiple NFs of the head, neck, brain, spinal cord and limbs. The patient underwent two craniotomies to remove intracranial lesions (pathology report: gliomas). She also had to remove up to fifteen subcutaneous lesions from the scalp, back, hand and breast with a pathology showing NFs.

On physical examination, no *café-au-lait* spots were noted. On panoramic X-rays a homogeneous oval radiolucency was noted in the right posterior side of the mandible, involving the mandibular canal with no resorption of the dental roots. A computed tomography (CT) scan showed a right mandibular cystic mass in the body of the mandible (below teeth 45-46-47; Figure 1).

Surgery was done as following: An incision in the right lower vestibular sulcus was done with dissection in the subperiosteal plane facing the lesion, reaching the mandibular angle. Drilling of the external cortex followed, with identification of the

Correspondence: Loubna Abboud, Division of Plastic and Reconstructive Surgery, Lebanese Hospital Geitaoui, University Medical Center, Lebanese University, Beirut, Lebanon.
Tel. +961.3.229965.

E-mail: loubna.abboud@gmail.com

Key words: Mandibular neurofibroma; Cystic mass; Surgery.

Conflict of interest: the authors declare no potential conflict of interest.

Funding: none.

Ethical statement: informed consent was obtained from the patient.

Received for publication: 24 February 2019.

Revision received: 24 October 2019.

Accepted for publication: 25 October 2019.

This work is licensed under a Creative Commons Attribution NonCommercial 4.0 License (CC BY-NC 4.0).

©Copyright: the Author(s), 2019

Licensee PAGEPress, Italy

Clinics and Practice 2019; 9:1143

doi:10.4081/cp.2019.1143

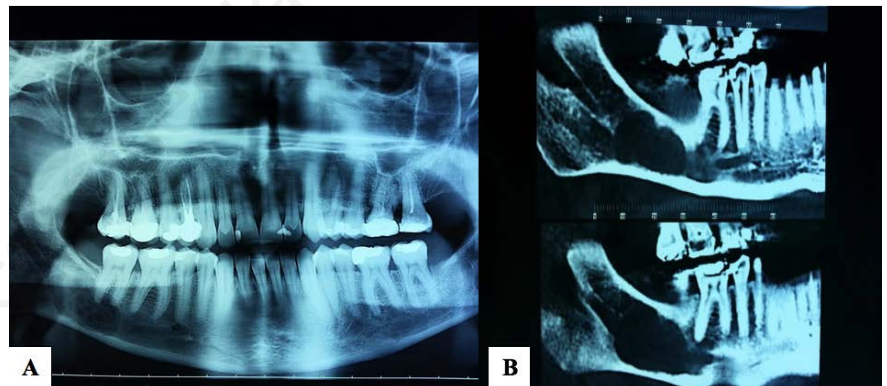


Figure 1. Right posterior mandibular radiolucency suggesting a cystic mass.

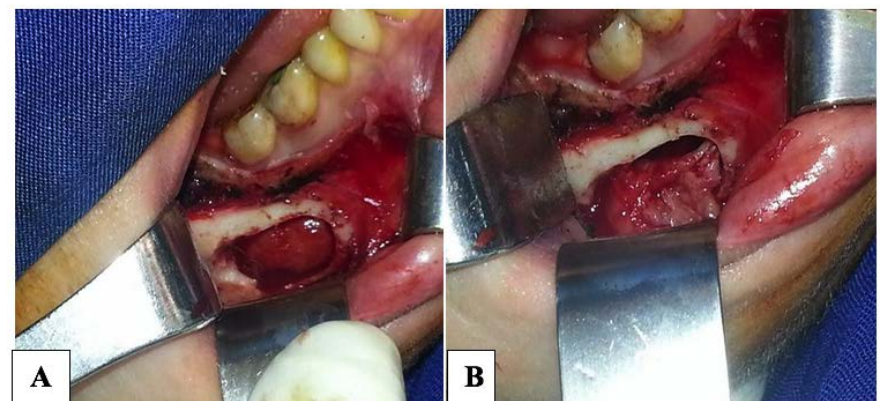


Figure 2. A) Intraoperative dissection showing oval cystic mass after drilling of the mandibular cortex. B) Intraoperative excision of the mandibular intraosseous mass.

lesion: a semi solid mass, oval shaped (2.5×1×1 cm; Figure 2).

The inferior alveolar nerve was found to be involved within the lesion, therefore it could not be salvaged and was excised

simultaneously. The lesion was resected *en bloc* with the nerve. A plate with 4 screws was used to prevent any possible fracture of the mandible (Figure 3).

Pathology results confirmed the diagno-

sis of a NF (Figure 4).

Discussion

Approximately 25% of the NFs occur in the head and neck region, while 5,6% of them occur in the oral cavity.⁶

As a rule, macroscopically, tumors are not encapsulated and have a softer consistency though the presentation may vary from case to case.^{7,8} Microscopically, NFs contain all the components of a peripheral nerve, with a predominance of schwann cells, that can be detected as small round to spindle shaped cells with wavy nuclei showing a serpentine configuration and pointed ends. Collagen fibers are seen in the stroma arranged in a characteristic *shredded carrot pattern*.⁷

Differential diagnosis of NFs include other spindle cell lesions like schwannoma, traumatic neuroma, desmoplastic melanotic melanoma, benign fibrous histiocytoma, spindle carcinoma and amelanotic melanoma.²

In their review of 66 cases of NFs, Polak *et al.* revealed the following distribution in the head and neck region:⁹ mandibular ridge/vestibule (22.7%), tongue (18.18%), palate (18.18%), buccal mucosa (15.15%), maxillary ridge/vestibule (13.6%), lip (6%), mandibular/intrabony (3%), gingiva (1.5%), floor of mouth (1.5%). Our patient had a rare form of intrabony mandibular NF with very few cases reported worldwide.

In its early stage, the mandibular NF is asymptomatic but as it increases in size, it may cause bone destruction along with pain and numbness of the lower lip.¹⁰ According to Che *et al.*,¹¹ a higher number of NFs can be observed in the posterior part of the mandible.² Larsson *et al.* reported symptoms like pain, swelling and osteolysis,¹² while Gujjar *et al.* reported a chief complaint of swelling of the left lower hemiface in a 27-year-old female with a solitary intraosseous NF of the mandible.² Another 62-year-old edentulous female patient presented with facial asymmetry.¹ In our case the patient had intermittent facial pain with lip and chin paresthesia due to involvement of the inferior alveolar nerve.

Surgical removal is the treatment of choice for solitary NF.¹ Radical surgery consisting of hemimandibulectomy or *en bloc* resection of the mandible is often used as a treatment for intraosseous NF.⁴ Ueda *et al.* reported a case of solitary intraosseous NF of the mandible with segmental mandibulectomy as a surgical treatment.¹³ Concerning our patient, we chose to do an excision of the mass with preservation of the healthy bone, with fixation using a plate

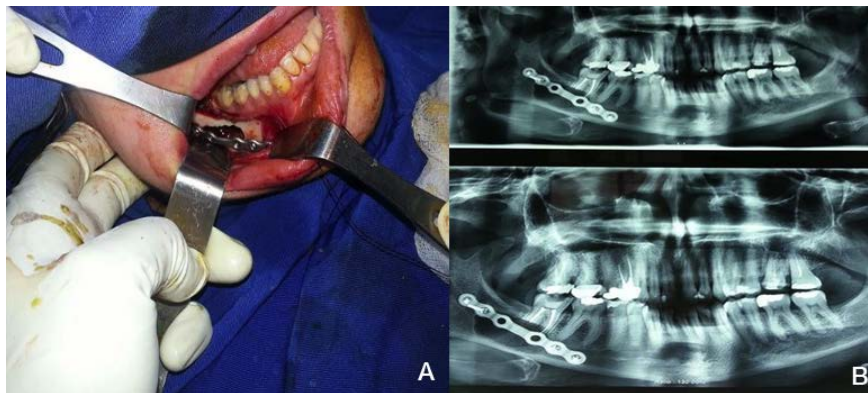

Figure 3. A) Intraoperative insertion of a plate with 4 screws (after removal of the cystic mass) to prevent any possible fracture of the mandible. B) Postoperative X-ray.

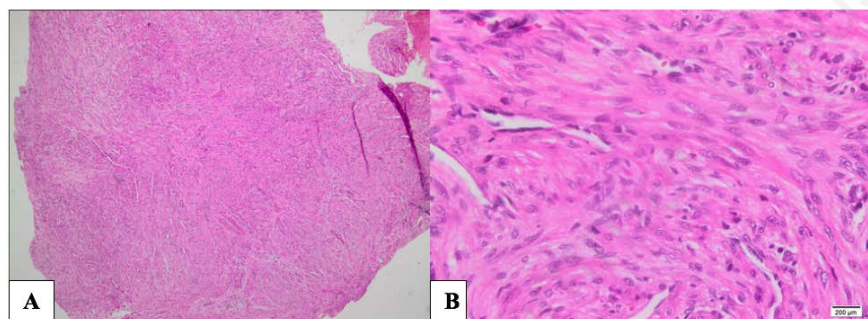


Figure 4. Hematoxylin-Eosin stain of the tumor. A) Magnification 4×. B) Magnification 40× showing spindle shaped cells with wavy nuclei and collagen fibers with a myxoid

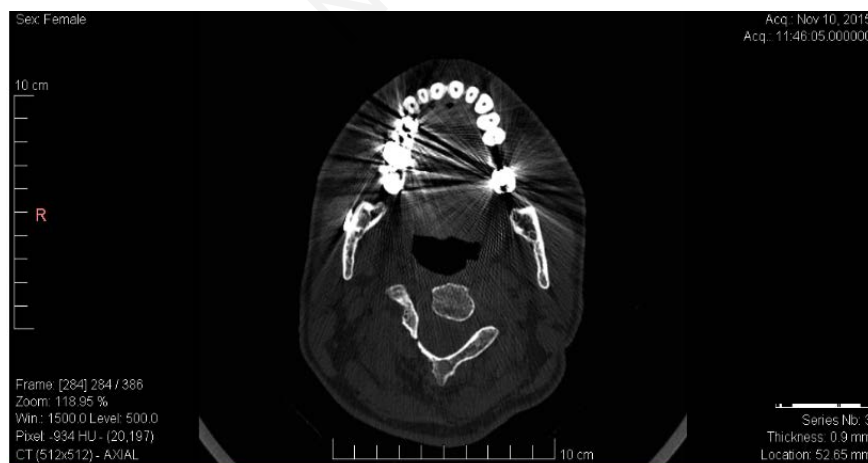


Figure 5. Coronal computed tomography scan 18 months after the operation showing no local recurrence.

and four screws in order to prevent any possible fracture of the fragilized mandible.

Local recurrence of NFs is rare and may be due to the incomplete surgical removal of the tumor attributed to the initial absence of the capsule,^{1,8} making complete surgical removal difficult. In our case, a clinical and radiological follow up were performed at 18 months post operatively: CT scan of the mandible showed no signs of recurrence (Figure 5). The patient complained of residual right lower lip paresthesia due to the resection of the right inferior alveolar nerve.

Conclusions

Although NFs are rare, their treatment can be challenging. Patients should be followed post operatively in order to detect recurrences that may be due to a lack of complete initial surgical excision.

References

- Jangam SS, Ingole SN, Deshpande, Ranadive PA. Solitary intraosseous neurofibroma: report of a unique case. *Contemp Clin Dent* 2014;5:561-3.
- Gujjar PK, Hallur JM, Patil ST, et al. The solitary variant of mandibular intraosseous neurofibroma: report of a rare entity. *Case Rep Dent* 2015;1-4.
- Bruce KW. Solitary neurofibroma (neurilemmoma, schwannoma) of the oral cavity. *Oral Surg Oral Med Oral Pathol* 1954;7:1150-9.
- Vivek N, manikandhan R, James PC, Rajeev R. Solitary intraosseous neurofibroma of mandible. *Indian J Dent Res* 2006;17:135-8.
- Deichler J, Martinez R, Niklander S, et al. Solitary intraosseous neurofibroma of the mandible, apropos of a case. *Med Oral Patol Oral Cir Bucal* 2011;16:e704-7.
- Marocchio LS, Oliveria DT, Pereira MC, et al. Sporadic and multiple neurofibromas in the head and neck region: a retrospective study of 33 years. *Clin Oral Investig* 2007;11:165-9.
- Narang BR, Palaskar SJ, Bartake AR, et al. Intraosseous neurofibroma of the mandible: a case report and review of Literature. *J Clin Diagn Res* 2017;11:ZD06-8.
- Apostolidis C, Anterriotis D, Rapidis AD, Angelopoulos AP. Solitary intraosseous neurofibroma of the inferior alveolar nerve: report of a case. *J Oral Maxillofac Surg* 2001;59:232-5.
- Polak M, Polak G, Brocheriou C, Vigneul J. Solitary neurofibroma of the mandible: case report and review of the literature. *J Oral Maxillofac Surg* 1989;47:65-8.
- Moradzadeh M, Vosough-Housseini S, Aghbali AA. Solitary neurofibroma of mandible in a 10 years old girl: report of a case. *Persian J Dent Shiraz Univ Med Sci* 2008;9:304-9.
- Che Z, Nam W, Park WS, et al. Intraosseous nerve sheath tumors in the jaws. *Yonsei Med J* 2006;47:264-70.
- Larsson A, Praetorius F, Hjärting-Hansen H. Intraosseous neurofibroma of the jaws. *Int J Oral Surg* 1978;7:494-9.
- Ueda M, Suzuki H, Kaneda T. Solitary intraosseous neurofibroma of the mandible: report of a case. *Nagoya J Med Sci* 1993;55:97-101.