

## Granulomatous lithiasic cholecystitis in sarcoidosis

Adriana Handra-Luca  
Department of Pathology, Paris Public Assistance Hospitals, North Paris Sorbonne Cité University, Avicenne Hospital University Group, Bobigny, France

### Abstract

Gallbladder granulomas are exceedingly rare, reported in association with tuberculosis or sarcoidosis. Here we report a case of gallbladder granulomatous cholecystitis occurring in the context of sarcoidosis. A 70-years old man presented with abdominal pain, nausea and vomiting. The medical history revealed sarcoidosis diagnosed more than 20-years previously. 2-years previously the patient showed renal lithiasis, hypercalcemia and, increased angiotensin converting enzyme. The imaging features suggested thoraco-abdominal sarcoidosis. Prednisone was given at 1.2 mg/kg/day initially, than decreased, being at 2.5 mg/day at present. The ultrasound examination showed gallbladder lithiasis. A cholecystectomy was performed. Microscopy showed subacute and chronic cholecystitis with several epithelioid and giant cell granulomas some of them perineural. In conclusion, we report a case of granulomatous cholecystitis occurring in the course of treated sarcoidosis. The perineural location of granulomas may give further insights into the pathogenesis of gallbladder dysmotility.

### Introduction

Granulomas in the gallbladder wall are exceedingly rare.<sup>1</sup> A case of granulomatous cholecystitis in the context of tuberculosis has been reported recently.<sup>2</sup> Here we report a case of gallbladder epithelioid and giant cell granulomas occurring in the course of treated thoraco-abdominal sarcoidosis and revealed by lithiasic cholecystitis.

### Case Report

The patient (man, 70-years old) presented with intermittent abdominal pain, nausea and vomiting over a period of more than 2 years. During this period of time, liver tests were fluctuant with constantly elevated alkaline phosphatases and gamma-glutamyl transpeptidase. The patient was diagnosed with lung sarcoidosis more than 20-years previously. The medical history revealed gastric ulcer and meniscal surgery (dates

unknown). Two years previously, the patient showed left renal lithiasis with acute renal failure and had ceftriaxone treatment. The patient also showed hypercalcemia, elevated angiotensin converting enzyme and, lymphopenia. His body mass index was 28.4 (overweight). The computed tomography (CT)-scan and positron-emission-scan were suggestive of thoraco-abdominal sarcoidosis by showing multiple hypermetabolic foci in the lymph nodes, liver and bone and, splenomegaly. A mild thickening of the gallbladder and biliary duct system walls, gallbladder lithiasis and infracentimetric adenopathies (gallbladder hilus, lomboarctic and aortomesenteric) were also detected (CT-scan). Treatments consisted in phloroglucinol/trimethylphloroglucinol, ketoprofen, paracetamol and fluticasone propionate. The corticoid treatment for sarcoidosis (begun 2-years previously) consisted in prednisone at a dose of 1.2 mg/kg/day. The dose was progressively decreased. At a treatment-dose of 10 mg, the patient showed nervousness and abdominal pain. The dose was decreased; at the moment of present explorations, the prednisone dose being of 2.5 mg/day. The ultrasound-examination made at this time, showed multiple gallbladder lithiasis and thin gallbladder and intra- and extrahepatic biliary ducts walls, without adipose infiltration. The patient did not show respiratory abnormalities. The preoperative diagnosis was that of symptomatic lithiasic gallbladder and a cholecystectomy was decided. The peroperative diagnosis was that of chronic cholecystitis. The peroperative cholangiography showed a lacuna of the terminal common bile duct without contrast substance in the duodenum. A calculus was extracted by cystic canal incision. On macroscopy, the resected gallbladder measured 6.5 cm and contained a 1-cm large stone. The microscopic examination revealed subacute and chronic lithiasic cholecystitis with several noncaseating epithelioid and giant cell granulomas. Mild fibrosis was observed in some granulomas. Most granulomas were situated in the subserosa, focally at contact to the serosa and/or to the muscle layer (Figure 1). Rare granulomas were in perineural location (with destruction of the epithelial membrane antigen-positive perineurium) or perivascular. The Ziehl-Neelsen stain did not show acid-fast bacilli. A Luschka-duct complex was seen, devoid of granuloma.

### Discussion and Conclusions

Sarcoidosis-type granulomatosis of the gallbladder is exceedingly rarely reported although the relatively frequent liver involvement (Table 1).<sup>1,3-5</sup> Granulomatous cholecystitis may be one of the revealing instances of sarcoidosis as seen in 2 of the 3 reported cases, to our knowledge.<sup>3,5</sup> The main clinical relevance resides in the treatments options, corticotherapy being given after cholecystectomy, in these 2 cases. In what concerns the reported cases of treated sarcoidosis, granulomas

Correspondence: Adriana Handra-Luca, Department of Pathology, Paris Public Assistance Hospitals, North Paris Sorbonne Cité University, Avicenne Hospital University Group, 125 rue Stalingrad, 93009 Bobigny, France.  
Tel.: +33.1489.55555/52047/5601 - Fax: +33.1489.5555602.  
E-mail: adriana.handra-luca@aphp.fr; adriana.handra-luca@hotmail.com

Key words: Gallbladder; cholecystitis; lithiasis; granuloma; nerve; perineural; sarcoidosis.

Acknowledgements: the author thanks Dr R. Munday as well as Dr B. Papouin, Dr J. Ladjici, Dr N. Turhan, Dr C. Allard, Dr G. Gianetti and Pr M. Batesti as well as V. Connan, V. Akdim, C. Van Vetteren, F. Spindler, L. Jovanovic, F. Buchard, I. Pluchard, B. Mechekour, J. Raleche, L. Delagarde, S. El-Sayeh, V. Ipotesi, N. Delva, N. Jalem, C. Almeida, M.C. Portenier, the NCA/APHP/Avicenne and, the CDMP/APHP.

Conflict of interest: the author declares no potential conflict of interest.

Received for publication: 29 September 2015

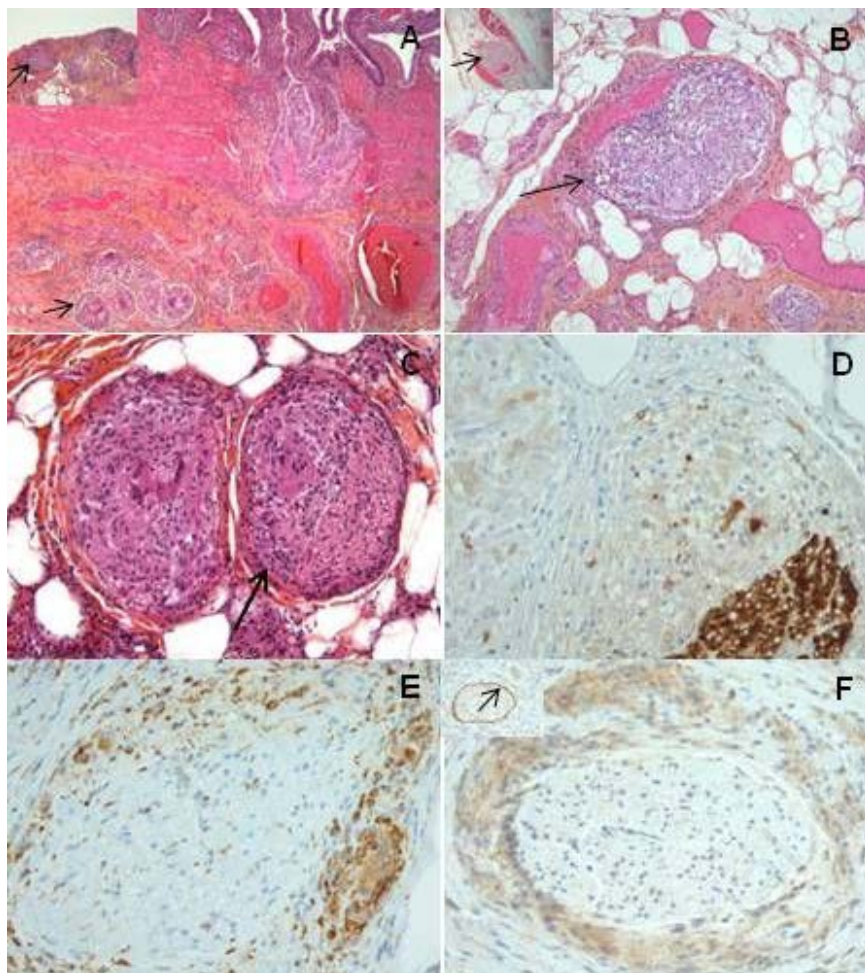
Revision received: 26 January 2016.

Accepted for publication: 15 February 2016

This work is licensed under a Creative Commons Attribution NonCommercial 4.0 License (CC BY-NC 4.0).

©Copyright A. Handra-Luca, 2016  
Licensee PAGEPress, Italy  
Clinics and Practice 2016; 6:811  
doi:10.4081/cp.2016.811

are reported in the gallbladder lymph nodes.<sup>6</sup> Of interest would also be the case of sarcoidosis reported by Kesici *et al.*<sup>7</sup> in which lymph node and not gallbladder granulomas were detected on the resected gallbladder diagnosed preoperatively with a gallbladder polyp. In the case we report, besides the location of granulomas in the gallbladder serosa, we have noted another morphological peculiarity, that of perineural granulomas. Interestingly, perineural granulomas have been recently reported in skin sarcoidosis.<sup>8</sup> Besides small-fiber-neuropathy with sensory disturbances, such lesions may result in abnormalities of the motor component and nerve-conduction including in asymptomatic sarcoidosis patients. However whether perineural granulomas along with those located at the contact of the gallbladder muscle layer, may interfere with dyskinesia, remains difficult to precise. However, in the case we report the pathogenesis of gallbladder dysmotility may be complex due to the presence of associated hypercalcemia, reported to interfere with gallbladder contraction.<sup>9</sup> In conclusion, the features of the case we report indicate that granulomatous cholecystitis may occur in corticoid-treated sarcoidosis. The tissue-specific location of granulomas such as perineural may give further insights in the pathogenesis of gallbladder dysmotility/dyskinesia.



**Figure 1.** The gallbladder wall showed several epithelioid and giant cell granulomas, some of them at contact to the serosa (A/arrow, A inset/arrow). Some granulomas were observed in perivascular (B/arrow, B inset/arrow) and perineural location (C-F, respectively). S100 was expressed in the nerve (D) while CD68 (E) was expressed in granuloma epithelioid and multinucleated giant cells. Epithelial membrane antigen-positive perineurium was destroyed by the granuloma (F) (non-specific positivity in epithelioid and multinucleated giant cells) while conserved in normal gallbladder nerves (F inset/arrow). Original magnification  $\times 2.5$  (A),  $\times 10$  (A inset, B inset),  $\times 20$  (C, E, F, F inset).

## References

1. Rosai J. Rosai and Ackerman's surgical pathology. Expert consult. Philadelphia, PA: Mosby Elsevier; 2011.
2. Kumar P, Hazrah P, Taneja A, et al. Rare presentation of gall bladder tuberculosis in a non immuno-compromised patient. Clin Pract 2015;5:754.
3. Lloyd-Davies RW, Forbes GB. Sarcoidosis of the gall bladder. Gastroenterology 1965;49: 287-90.
4. Mert A, Avsar S, Ozaras R, et al. Gall bladder involvement in sarcoidosis. J Clin Gastroenterol 2004;38:612-3.
5. Kusielewicz D, Duchatelle V, Valeyre D, et al. [Obstructive jaundice caused by granulomatous stenosis of the extrahepatic bile ducts in sarcoidosis]. Gastroenterol Clin Biol 1988; 12:664-7. [Article in French]
6. Freed JS, Reiner MA. Acute cholecystitis as a complication of sarcoidosis. Arch Intern Med 1983;143:2188-9.
7. Kesici B, Toros AB, Bayraktar L, Dervisoglu A. Sarcoidosis incidentally diagnosed: a case report. Case Rep Pulmonol 2014;2014: 702868.
8. Munday WR, McNiff J, Watsky K, et al. Perineural granulomas in cutaneous sarcoidosis may be associated with sarcoidosis small-fiber neuropathy. J Cutan Pathol 2015; 42:465-70.
9. Malagelada JR, Holtermuller KH, Sizemore GW, Go VL. The influence of hypercalcemia on basal and cholecystokinin-stimulated pancreatic, gallbladder, and gastric functions in man. Gastroenterology 1976;71:405-8.

**Table 1. Reported cases of gallbladder wall sarcoidosis.**

	Gender (years)	Age	Preoperative diagnosis	Gallbladder microscopy	Corticotherapy
Case 1, 1965 <sup>3</sup>	Man	19	Vomiting and pain (right hypochondrium), chronic cholecystitis (cholangiogram)	Panparietal gallbladder and liver noncaseating granulomas (no AFB); subacute cholecystitis	Post-surgical
Case 2, 1988 <sup>4</sup>	Woman	37	Jaundice and pruritus, treated thoraco-abdominal sarcoidosis (for 10 years)	Gallbladder neck noncaseating granulomas (no AFB)	Pre- and post-surgical
Case 3, 2004 <sup>5</sup>	Man	27	3 years previously biliary colic and multiple gallbladder stones (USE), 1 year previously biliary pancreatitis; 7 months previously inguinal adenopathies and dyspnea at effort (negative tuberculin skin reaction)	Gallbladder, liver and lymph node noncaseating granulomas (no AFB); chronic cholecystitis	Post-surgical

AFB, acid-fast bacilli (Ziehl-Neelsen stain); USE, ultrasound examination.