

Pediatric endobronchial inflammatory myofibroblastic tumor: a case report and review of the literature

Leilei Liu, Xianglei Kong, Xiaoqian Lu, Dianbo Cao

Department of Radiology, The First Hospital of Jilin University, Changchun, China

Abstract

Inflammatory myofibroblastic tumor (IMT) belongs to the group of soft tissue tumor and could occur at any anatomical site from the central nervous system to gastrointestinal tract. The lung and abdomen are commonly affected sites, however, pulmonary IMT is predominantly located within the parenchyma rather than presenting as endobronchial lesion. IMTs may occur in any age group, but they are observed most commonly in children and adolescents. Here, we present a case of IMT arising from the left main stem bronchus in a 10-year-old girl.

Introduction

Inflammatory myofibroblastic tumor (IMT) was first described by Brunn in 1939. According to the 2013 World Health Organization (WHO) Classification of soft tissue tumors, IMT has been defined as an intermediate fibroblastic or myofibroblastic tumor.¹ This lesion arises from soft tissue or viscera, which is characterized by the presence of spindle-shaped myofibroblasts, and a chronic inflammatory infiltrate composed of eosinophils, lymphocytes, and plasma cells. IMT can occur throughout the body, including the lung, bladder, spleen, breast, pancreas, liver, spermatic cord, prostate, peripheral nerves, soft tissue, and orbit. The true prevalence of IMT of the lung is difficult to calculate because varying terminology caused a great deal of confusion, but it accounts for 0.04-0.7% of all lung tumors across all age groups. Pulmonary IMT is predominantly located within the parenchyma rather than presenting as endobronchial lesions. Preoperative diagnosis of endobronchial IMT is quite difficult and requires a multi-disciplinary medical approach. Bronchoscopy and CT studies are the main methods to evaluate this rare disease entity. Bronchoscopy allows only a visual evaluation of the tumor surface and subsequent biopsy. Other information about the origin,

internal composition, enhancement pattern and extent of the lesion can be easily obtained through contrast-enhanced CT scan. IMT can be suspected preoperatively through some hematologic abnormalities and radiologic findings, but correct diagnosis mainly depends on histopathological findings.² Endobronchial IMT in the pediatric population is relatively rare and nearly 136 cases have been reported up to date in the English literature.³⁻²⁹ Because of rarity of endobronchial IMT, the experience regarding imaging evaluation, treatment and long-term outcomes need to be further accumulated. Therefore, we present the clinical and radiological features of an additional case.

Case Report

A 10-year-old girl complaining of a progressive shortness of breath was admitted to our hospital. She repeatedly suffered from pneumonia for the past 3-year. Meanwhile, she also described chest tightness and intermittent dyspnea on exertion exercise. She did not have other systemic symptoms such as pyrexia, abdominal pain, weight loss and night sweat. Physical examination revealed a well-nourished girl without acute distress. Her vital signs were normal, and oxygen saturation on room air was 99%. There was no thyromegaly, jugular venous distention or cervical lymphadenopathy. Rhonchi and wheezing were heard in the left lung field. The cardiac examination and abdominal examination were unremarkable. Erythrocyte sediment reaction and C-reactive protein were elevated with the value of 63mm/h and 32mg/L respectively. Tuberculin skin test was negative. Chest radiography showed increased opacity over left lung field and mediastinal shift to the left, suggesting the collapse of the left lung. Non-enhanced computed tomography showed typical obstruction of the left main bronchus associated with complete left lung atelectasis. Subsequent contrast-enhanced CT showed a significantly enhanced oval mass measuring 1.0×2.0×2.2 cm within the left main bronchus (Figure 1), which completely obstructed the distal portion of the left main stem bronchus and its branches. There was no evidence of mediastinal infiltration and lymphadenopathy. At the bronchoscopic examination, an oval vessel-rich mass was noted at the distal end of the left main bronchus and causing a complete occlusion of the lumen (Figure 2). Considering the appearances of contrast-enhanced CT suggesting vessel-rich lesions, endoscopic resection of the tumor was not a candidate.

Radical surgical resection of the mass was proposed to the patient's parents and informed consent was granted. Under general anesthesia, the patient underwent total resection of

Correspondence: Dianbo Cao, Department of Radiology, The First hospital of Jilin University, XinMin Street 71, Chang Chun, 130021, China. Tel.: 86.431.88782911. E-mail: caotianbo@126.com

Key words: Inflammatory myofibroblastic tumor; pediatric; endobronchial.

Received for publication: 17 April 2016.

Revision received: 13 November 2016.

Accepted for publication: 17 November 2016.

This work is licensed under a Creative Commons Attribution NonCommercial 4.0 License (CC BY-NC 4.0).

©Copyright L. Liu et al., 2016

Licensee PAGEPress, Italy

Clinics and Practice 2016; 6:853

doi:10.4081/cp.2016.853

the tumor and the left main bronchus and bronchoplasty through a left posterolateral 5th intercostal space. The resected neoplasm was gray-yellow, solid and gritty. Microscopic findings visualized a cellular lesion characterized by abundant spindle-shaped cells and inflammatory cells (HE×200) (Figure 3). Immunohistochemically, the tumor was positive for desmin, smooth muscle actin and anaplastic lymphoma kinase (ALK), and negative for CD117, CD34, S-100. The tumor had a low Ki-67 proliferative index. Based on histopathological findings and immunohistochemical analysis, a diagnosis of endobronchial IMT was made. The postoperative period was uneventful and the patient was discharged on the 10th postoperative day. The child was growing well with no sign of relapse on the 6th month follow-up. A check-up bronchoscopy was reported to be normal and follow-up CT showed complete resolution of the left lung atelectasis (Figure 4).

Discussion

IMT was first observed in lung and described by Brunn in 1939, and was named by Umiker *et al.* in 1954 owing to its propensity to clinically and radiologically mimic a malignant process.³⁰ IMT has ever been described by various terms because of its variable cellular components, which include plasma cell granuloma, inflammatory pseudotumor, xanthogranuloma, inflammatory fibrosarcoma, and pseudosarcomatous myofibroblastic proliferation. However, these names are unified as inflammatory myofibroblastic tumor. It can almost be found in every site of the body from the central nervous system to gastrointestinal tract, but the lung and abdomen are commonly affected loca-

tion. IMT can occur at any age and both sexes are equally affected. A large series study by Coffin *et al.* reviewed 84 cases with IMT involving various sites, the age of these patients ranges from 3 months to 46 years.³¹ In the pediatric patients with primary pulmonary tumors, IMT constitutes approximately 50% of benign intrapulmonary tumor. However, pulmonary IMT is predominantly located within the parenchyma rather than presenting as endobronchial lesion.³ But endobronchial IMT in the pediatric population is not rare with more than 136 cases reported in the English literature up to date,³⁻²⁹ and 10 cases was listed in the table for the available result of ALK analysis (Table 1).³⁻¹⁰

Among 6 children, ALK translocation/over-expression was definite. The positive rate of ALK in children with endobronchial IMT is similar to that in all IMT patients.

IMT is poorly understood about its etiology. Trauma, surgery, infections *i.e.* herpes and Epstein-Barr virus, radiotherapy, steroid use and autoimmune reactions have been suggested as etiological factors.³² By several authors, it was postulated that pulmonary inflammatory pseudotumors occur as a result of unchecked immunologic response to a viral or foreign antigen-antibody reaction.^{33,34} But in endobronchial IMTs, pneumonia is more likely to be a common obstructive pulmonary outcome rather than a cause of it.²⁰ Currently, IMT is mostly considered as a neoplasm of intermediate malignant potential as evidenced by the fact that nearly 50-70% of the cases carry rearrangements of *ALK* gene.³⁵ *ALK* gene, located on the short arm of chromosome 2 at 2p23, encodes a tyrosin kinase receptor.³⁶ Its expression is normally restricted to the brain, particularly in the developing nervous system. *ALK* is involved in the pathogenesis of several tumors, and anaplastic large cell lymphoma is the most famous one. This is also seen in at least a part of IMTs. The *ALK* status has a role in a number of differential diagnoses. In fact, the majority of the lesions that enter the differential diagnosis with IMT are *ALK*-negative.^{38,39} *ALK* gene could be a potential target molecule, and specific targeted therapy, such as tyrosine kinase inhibition, has been used in selected inflammatory myofibroblastic tumors with encouraging results, as noted by Butrynsky.³⁹ Though more study needed, the response of IMT to tyrosine kinase inhibition may be another evidence for the influence of *ALK* to this group of diseases.

The clinical presentations of pulmonary IMT can be variable ranging from asymptomatic to variable symptoms. Most presented symptoms are cough, hemoptysis, chest pain and dyspnea, and fever. After the surgical resection, the systemic symptoms of IMT may resolve and tumor recurrence may be found easily by a return of clinical abnormalities.²

Radiologic findings of pulmonary IMT are variable and unspecific. The most common radiological presentation is a solitary peripheral well-circumscribed lung mass, with variable size between 1.5 cm and 14 cm according to a series of 28 cases reported by Kim *et al.*⁴⁰ Endobronchial polypoid forms arising in the bronchus are the rarest but have also been reported, and chest radiography only reveals non-specific finding such as pulmonary atelectasis or obstructive pneumonia. Non-enhanced CT can be helpful in identify intralesional calcifications, which are shown more frequently in pediatric cases. Dynamic contrast-enhanced CT can show the origin, internal component, enhancement pattern and extent of the lesion. Regarding the dynamic enhancement features, Takayama *et al.*⁴¹ speculate that delayed enhancement could be attributed to abundant fibrous tissues such as myofibroblasts, which were the main structural material of the tumor.

The treatment of choice for IMT remains controversial, and appropriate management should be based on the site of tumor and the condition of the patient. The common option of therapeutics includes surgical resection, corticosteroids and non-steroidal anti-inflammatory drugs (NSAID). Although surgical intervention in child is challenging, the surgical resection is very important in complete removal and good prognosis. For those patients who are unsuitable for complete surgical resection such as the case of multiple tumors or mass infiltrating adjacent organs, other modalities can be considered. There are also sporadic reports of rapid and sustained resolution with corticosteroid monotherapy and NSAIDs.^{42,43} There are also sporadic reports of success with laser, but some authors point that it can result in recurrent relapse of IMT.¹²

The prognosis of IMT is usually good, but it depends on tumor size (less than or equal to 3 cm) and complete resection. The overall 3-year

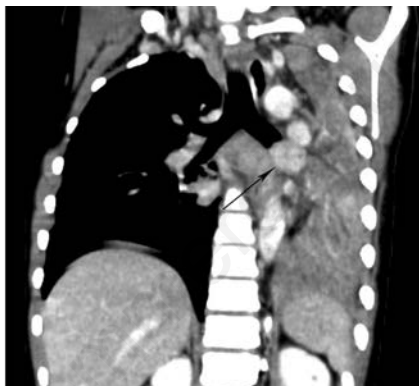

Figure 1. Contrast-enhanced reformatted coronal image showed a significantly enhanced oval mass situating within the left main bronchus, which completely obstructed the left main stem bronchus.

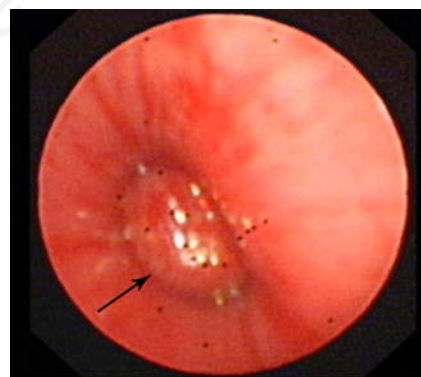


Figure 2. Bronchoscopic examination revealed an ovular neoplasm with rich vessels.

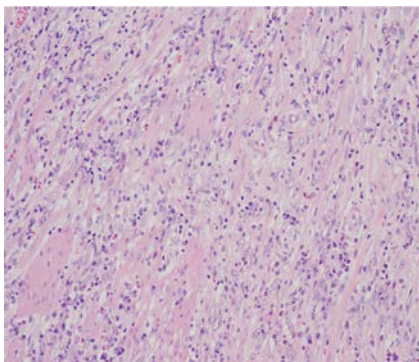


Figure 3. Microscopic examination show a cellular lesion characterized by myofibroblast-like spindle cells admixed with abundant acute or chronic inflammatory cells (HE×200).

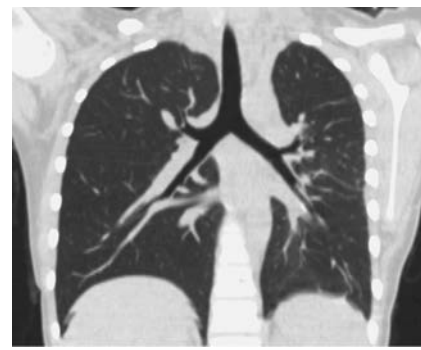


Figure 4. Follow-up computed tomography showed the norm of the left lung on post-operative 12 months.

Table 1. Cases of children with endobronchial inflammatory myofibroblastic tumor and available results of anaplastic lymphoma kinase staining.

Study	Age (y)	Gender	Localization	Size (mm)	Follow-up period (months)	ALK translocation/over-expression
Uchida <i>et al.</i> ⁴	9	M	RMB	14	12	Positive
Fujino <i>et al.</i> ⁵	10	F	RB	-	6	Positive
Dhouib <i>et al.</i> ⁶	11	M	LMB	18×12×17	3	Positive
Karnak <i>et al.</i> ³	9	F	LMB	-	3	Negative
Singh <i>et al.</i> ⁷	12	M	RUL	9	-	Positive
Brodlie <i>et al.</i> ⁸	15	F	LMB	-	36	Positive
Brodlie <i>et al.</i> ⁸	11	M	Trachea	-	18	Negative
Sacco <i>et al.</i> ⁹	6	F	RUL	-	16	Negative
İcmeli <i>et al.</i> ¹⁰	16	F	RUL	40	-	Negative
Present study	10	F	LMB	20×20×12	6	Positive

F, female; M, male; LMB, left main bronchus; RMB, right main bronchus; RB, right bronchus; RUL, right upper lobe; RML, right middle lobe.

survival rate is about 82% and the overall 5-year survival rate is about 74%.⁴⁴ Local recurrence rate of pulmonary IMT after resection was between 6.6% and 13%, occurring predominantly in those cases with incomplete resection. Rare distant metastases have also been reported due to multifocal characteristic of this disease entity rather than metastatic spread. Close follow-up radiological studies are strongly recommended. Bronchoscopy should also be planned even if postoperative radiologic images are normal. We are confident that complete resection was achieved in our case, follow-up bronchoscopy and CT showed no evidence of tumor. Although rare, endobronchial IMT should be known as a possible cause of atelectasis in children. Imaging findings together with appropriate management in our patient will further accumulate clinical experiences of IMT.

References

- Fletcher CDM, Bridge JA, Hogendoorn PCW, Mertens F. World Health Organization classification of soft tissue and bone tumors. Lyon: IARC Press; 2013.
- Karnak I, Senocak ME, Ciftci AO, et al. Inflammatory myofibroblastic tumor in children: diagnosis and treatment. *J Pediatr Surg* 2001;36:908-12.
- Karnak I, Haliloglu M, Orhan D, Yet al. Pure endobronchial inflammatory myofibroblastic tumor in children. *J Pediatr Hematol Oncol* 2014;36:108-10.
- Uchida DA, Hawkins JA, Coffin CM, Grimmer JF. Inflammatory myofibroblastic tumor in the airway of a child. *Ann Thorac Surg* 2009; 87:610-3.
- Fujino H, Park YD, Uemura S, et al. An endobronchial inflammatory myofibroblastic tumor in a 10-yr-old child after allogeneic hematopoietic cell transplantation. *Pediatr Transplant* 2014;18:165-8.
- Dhouib A, Barrazzone C, Reverdin A, et al. Inflammatory myofibroblastic tumor of the lung: a rare cause of atelectasis in children. *Pediatr Radiol* 2013;43:381-4.
- Singh S, Dorfman SR, Nuctern JG, et al. Recurrent pneumonias secondary to an endobronchial inflammatory myofibroblastic tumor. *Am J Respir Crit Care Med* 2013;187:e1-2.
- Brodlie M, Barwick SC, Wood KM, et al. Inflammatory myofibroblastic tumours of the respiratory tract: paediatric case series with varying clinical presentations. *J Laryngol Otol* 2011;125:865-8.
- Sacco O, Gambini C, Gardella C, et al. "Atypical steroid response" in a pulmonary inflammatory myofibroblastic tumor. *Pediatr Pulmonol* 2010;45:721-6.
- Icmeli OS, Alpay LA, Gundogus B, et al. Inflammatory myofibroblastic tumor: a rare tumor of the lung. *Eur Clin Respir J* 2014;1.
- Pan W, Du L, Wu Y, Cai W. Successful sleeve lobectomy of inflammatory myofibroblastic tumor in a 4-year-old child. *Ann Thorac Cardiovasc Surg* 2014;20:430-3.
- Breen DP, Dubus JC, Chetaille B, et al. A rare cause of an endobronchial tumour in children: the role of interventional bronchoscopy in the diagnosis and treatment of tumours while preserving anatomy and lung function. *Respiration* 2008;76:444-8.
- Chen D, Ryan G, Edwards M. Bronchial sleeve resection for a patient with an inflammatory pseudotumour. *Anz J Surg* 2001;71:187-9.
- Hancock BJ, Di Lorenzo M, Youssef S, et al. Childhood primary pulmonary neoplasms. *J Pediatr Surg* 1993;28:1133-6.
- Roby BB, Drehner D, Sidman JD. Pediatric tracheal and endobronchial tumors: an institutional experience. *Arch Otolaryngol Head Neck Surg* 2011;137:925-9.
- Kim TS, Han J, Kim GY, et al. Pulmonary inflammatory pseudotumor (inflammatory myofibroblastic tumor): CT features with pathologic correlation. *J Comput Assist Tomogr* 2005;29:633-9.
- Hajjar WA, Ashour MH, Al-Rikabi AC. Endobronchial inflammatory pseudotumor of the lung. *Saudi Med J* 2001;22:366-8.
- Hoseok I, Joungho H, Ahn KM, et al. Complete surgical resection of inflammatory myofibroblastic tumor with carinal reconstruction in a 4-year-old boy. *J Pediatr Surg* 2005;40:e23-5.
- Cerfolio RJ, Matthews TC. Resection of the entire left mainstem bronchus for an inflammatory pseudotumor. *Ann Thorac Surg* 2005;79:2127-8.
- El-Desoky T, Nasef N, Osman E, et al. Endobronchial inflammatory pseudotumor: a rare cause of a pneumothorax in children. *J Bronchology Interv Pulmonol* 2013;20:256-60.
- Cohen MC, Kaschula RO. Primary pulmonary tumors in childhood: a review of 31 years' experience and the literature. *Pediatr Pulmonol* 1992;14:222-32.
- Spencer H. The pulmonary plasma cell/histiocytoma complex. *Histopathology* 1984;8:903-16.
- Warter A, Satge D, Roeslin N. Angioinvasive plasma cell granulomas of the lung. *Cancer-AM Cancer Soc* 1987;59: 435-43.
- Maier HC, Sommers SC. Recurrent and metastatic pulmonary fibrous histiocytoma/plasma cell granuloma in a child. *Cancer-AM Cancer Soc* 1987;60:1073-6.
- Pettinato G, Manivel JC, De Rosa N, Dehner LP. Inflammatory myofibroblastic tumor (plasma cell granuloma). Clinicopathologic study of 20 cases with immunohistochemical and ultrastructural observations. *AM J Clin Pathol* 1990;94: 538-46.
- Schwartz EE, Katz SM, Mandell GA. Postinflammatory pseudotumors of the

- lung: fibrous histiocytoma and related lesions. *Radiology* 1980;136:609-13.
27. Katzenstein AL, Gmelich JT, Carrington CB. Sclerosing hemangioma of the lung: a clinicopathologic study of 51 cases. *Am J Surg Pathol* 1980;4:343-56.
 28. Bahadori M, Liebow AA. Plasma cell granulomas of the lung. *Cancer-Am Soc* 1973;31:191-208.
 29. Berardi RS, Lee SS, Chen HP, Stines GJ. Inflammatory pseudotumors of the lung. *Surg Gynecol Obstet* 1983;156:89-96.
 30. Umiker Wo, Iverson L. Postinflammatory tumors of the lung; report of four cases simulating xanthoma, fibroma, or plasma cell tumor. *J Thorac Surg* 1954;28:55-63.
 31. Coffin CM, Watterson J, Priest JR, Dehner LP. Extrapulmonary inflammatory myofibroblastic tumor (inflammatory pseudotumor). A clinicopathologic and immunohistochemical study of 84 cases. *Am J Surg Pathol* 1995;19:859-72.
 32. Coffin CM, Hornick JL, Fletcher CD. Inflammatory myofibroblastic tumor: comparison of clinicopathologic, histologic, and immunohistochemical features including ALK expression in atypical and aggressive cases. *Am J Surg Pathol* 2007;31:509-20.
 33. Herman PG, Hillman B, Pinkus G, Harris GC. Unusual noninfectious granulomas of the lung. *Radiology* 1976;121:287-92.
 34. Shirakusa T, Miyazaki N, Kitagawa T, Sugiyama K. Ultrastructural study of pulmonary plasma cell granuloma--report of a case. *Br J Dis Chest* 1979;73:289-96.
 35. Coffin CM, Patel A, Perkins S, et al. ALK1 and p80 expression and chromosomal rearrangements involving 2p23 in inflammatory myofibroblastic tumor. *Mod Pathol* 2001;14:569-76.
 36. Morris SW, Kirstein MN, Valentine MB, et al. Fusion of a kinase gene, ALK, to a nucleolar protein gene, NPM, in non-Hodgkin's lymphoma. *Science* 1994;263:1281-4.
 37. Rao RN, Ranjan P, Singla N, Pandey R. Inflammatory myofibroblastic tumor of the urinary bladder diagnosed by anaplastic lymphoma kinase immunostaining. *Urol Ann* 2012;4:115-8.
 38. Sukov WR, Cheville JC, Carlson AW, et al. Utility of ALK-1 protein expression and ALK rearrangements in distinguishing inflammatory myofibroblastic tumor from malignant spindle cell lesions of the urinary bladder. *Mod Pathol* 2007;20:592-603.
 39. Butrynski JE, D'Adamo DR, Hornick JL, et al. Crizotinib in ALK-rearranged inflammatory myofibroblastic tumor. *N Engl J Med* 2010;363:1727-33.
 40. Karnak I, Senocak ME, Ciftci AO, et al. Inflammatory myofibroblastic tumor in children: diagnosis and treatment. *J Pediatr Surg* 2001;36:908-12.
 41. Takayama Y, Yabuuchi H, Matsuo Y, et al. Computed tomographic and magnetic resonance features of inflammatory myofibroblastic tumor of the lung in children. *Radiat Med* 2008;26:613-7.
 42. Carswell C, Chataway J. The successful long-term management of an intracranial inflammatory myofibroblastic tumor with corticosteroids. *Clin Neurol Neurosurg* 2012;114:77-9.
 43. Chavez C, Hoffman MA. Complete remission of ALK-negative plasma cell granuloma (inflammatory myofibroblastic tumor) of the lung induced by celecoxib: a case report and review of the literature. *Oncol Letter* 2013;5:1672-6.
 44. Melloni G, Carretta A, Ciriaco P, et al. Inflammatory pseudotumor of the lung in adults. *Ann Thorac Surg* 2005;79:426-32.