

A child with debilitating pruritus

Nikhil Sonthalia,¹ Samit S. Jain,¹
Vinay B. Pawar,¹ Vinay G. Zanwar,¹
Ravindra G. Surude,¹ Pravin M. Rath,¹
Kshitij K. Munde,² Sandeep Bavdekar²

¹Department of Gastroenterology;

²Department of Pediatric Medicine;
Topiwala National Medical College and
BYL Nair Ch Hospital, Mumbai,
Maharashtra, India

Abstract

We describe a case of two-year-old boy presenting with debilitating pruritus, patchy alopecia and jaundice since the age of 6 months. On evaluation he had intrahepatic cholestasis with persistently raised serum alkaline phosphatase, normal Gamma glutamyl transferase and raised serum bile acid levels. His liver biopsy showed bland cholestasis and electron microscopy showed granular bile suggestive of progressive familial intrahepatic cholestasis type I. Medical therapy with ursodeoxycholic acid, cholestyramine, rifampicin with nutritional modification was successful in alleviating the symptoms and correcting the nutritional status. To our knowledge this is only the sixth case of progressive familial intrahepatic cholestasis type I reported from India. Herein we discuss the diagnostic and therapeutic hurdles that one encounters in managing progressive familial intrahepatic cholestasis and also review the literature regarding this rare disorder.

Introduction

Progressive familial intrahepatic cholestasis (PFIC) is a rare, heterogeneous group of cholestatic liver disorders manifesting in infancy or early childhood.¹ PFIC I is the subtype of this group which is characterized by intrahepatic cholestasis, intense pruritus, normal or low gamma glutamyl transferase (GGT), and characteristic *O Bylers bile* on electron microscopy.^{2,3} We describe here a case of two-year child presenting with complaints of debilitating pruritus since the age of 6 months with malnourishment associated with patchy alopecia, secondary ichthyosis, darkening and lichenification of skin. His serum alkaline phosphatase (ALP) was raised, along with normal GGT and mild hyperbilirubinemia. Histopathological examination of liver was suggestive of bland intrahepatic cholestasis. Electron microscopy demonstrated granular

bile suggesting the diagnosis of PFIC I. The patient was treated with cholestyramine, ursodeoxycholic acid and rifampicin which relieved his pruritus and hair loss. Extensive literature search revealed only handful of case reports of this rare disorder reported from India with no data available regarding the prevalence of PFIC in India. The diagnostic and therapeutic challenges Indian gastroenterologists face are due to lack of easily available genetic testing facility and limited experience in managing these patients. Herein we discuss these aspects together with review of literature regarding this rare disorder.

Case Report

A two-year boy, born out of a consanguineous marriage with full term normal delivery and no perinatal complications presented with history of itching which was generalized, severe and progressive associated with growth failure since the age of six months. He also developed patchy alopecia since the age of one year. Mother noticed jaundice since the age of one year associated with intense pruritus, without prodromal symptoms. According to her the jaundice was fluctuating since then. There was no history of any hepatotoxic drug exposure, fever, hematemesis, melena, abdominal distension, abdominal pain and diarrhea. Patient was initially evaluated by a dermatologist for pruritus, later was referred to us due to no relief of symptoms.

On examination patient was <5th percentile for his weight and height (6.5 kg and 75 cm respectively). His pulse rate was 102/min, blood pressure 90/60 mm of Hg. He was irritable, restless with evidence of excoriated skin, lichenification, itch marks all over the body and shiny nails (Figure 1A). There were patchy areas of alopecia on scalp (Figure 1B). There was no clinical evidence of lymphadenopathy, peripheral edema, pallor or icterus. There was hepatomegaly of 3 cm, with liver span of 15 cm, which was firm, non-tender, smooth surface with rounded margin. Spleen was palpable for 3 cm along the splenic axis.

His routine blood biochemical parameters over past six months is depicted in Table 1. It showed mildly increased serum aminotransferase levels (<2 times of upper normal limit), mild direct hyperbilirubinemia, persistently raised ALP (>5 times of upper normal limit) which had not changed over past six months. His GGT was 28 U/L (normal up to 75 U/L). Blood for HBsAg and anti-hepatitis C virus were negative. Serum autoimmune markers including anti-nuclear antibody, anti-smooth muscle antibody, anti-liver kidney microsomal type 1 antibody were negative. Serum Immunoglobulin and serum ceruloplasmin

Correspondence: Nikhil Sonthalia, Department of Gastroenterology, Topiwala National Medical College and BYL Nair Ch Hospital, Dr. A.L Nair Road, Mumbai - 400008, Mumbai, Maharashtra, India.

Tel.: 022.23021639.

E-mail: nikhil_zenith@yahoo.co.in

Key words: Progressive familial intrahepatic cholestasis; bland cholestasis; granular bile; pruritus; alopecia.

Acknowledgments: we would like to thank Dr. Prateek Oswal, Consultant Dermatologist, Mumbai, India for his valuable input in evaluation of the patient.

Contributions: All authors contributed equally to the manuscript; NS, SP, AM, designed and wrote the manuscript; SJ, NS, KM evaluated the patient and did the literature search and recorded clinical findings; RS, PMR, SB conceptualised the manuscript, gave the intellectual input and did critical review of the manuscript.

Conflict of interest: authors have no conflict of interest.

Received for publication: 21 June 2016.

Revision received: 28 August 2016.

Accepted for publication: 22 September 2016.

This work is licensed under a Creative Commons Attribution NonCommercial 4.0 License (CC BY-NC 4.0).

©Copyright N. Sonthalia et al., 2016
Licensee PAGEPress, Italy
Clinics and Practice 2016; 6:865
doi:10.4081/cp.2016.865

were normal. Ultrasonography showed mild hepatosplenomegaly, preserved hepatic echotexture, normal gall bladder, common bile ducts and intra hepatic biliary radicles.

Subsequently serum bile acid level was done which was 88 mcmo/L (normal <10 mcmo/L). Next we did liver biopsy for evaluating the cause of intra hepatic cholestasis. It revealed hepatocytes showing feathery and hydropic changes with intrahepatic cholestasis, without significant portal inflammation, unremarkable bile ducts together with no evidence of fibrosis, bile duct proliferation or giant cell hepatitis. All these features represented bland cholestasis (Figure 2A). We diagnosed this case as PFIC with type I being more likely than type II in view of the liver biopsy findings. Subsequently electron microscopy from liver biopsy was done which showed distended bile canaliculi with coarse and granular bile confirming the diagnosis of PFIC I (Figure 2B).

He was given adequate sunlight exposure, moisturizing lotions, nutritional supplement of vitamin A, D, E and K. He was given total calorie intake of 125% of recommended dietary

allowance. Initially ursodeoxycholic acid (UDCA) in dose of 12 mg/kg/day in 3 divided dose, and cholestyramine 2 mg/day in 4 divided dose was given. However, as there was only partial relief of symptoms after 4 weeks, rifampicin 2.5 mg/kg/day in 2 divided doses was then added. Combined therapy was successful in alleviating his pruritus and hair loss by the end of two months (Figure 1C and D). Biliary diversion was not offered as he responded to medical therapy. Patient is currently on our active follow up and shows complete resolution of skin changes and pruritus. Liver function is also stabilized with normal AST and ALT levels and marginally deranged bilirubin (fluctuating between 1-2 mg/dL). However, parents were counseled for the need of liver transplant in future if end-stage liver disease (ESLD) occurs or if there is recurrence of intractable pruritus not responding to medication.

Discussion

Initially described in Amish descendants of Jacob Byler by Clayton *et al.* in 1965, PFIC was originally named Byler disease.⁴ Subsequently, numerous phenotypically similar non-Amish patients were reported, and the term Byler syndrome was used to describe these conditions. It has an autosomal recessive pattern of inheritance and both the sexes are affected equally. Though the Western data suggests an incidence of 1 per 50,000 to 1 per 100,000 births, no data is available regarding its prevalence from India.³ Though cholestatic jaundice in infancy is not an uncommon disorder in India, diagnosing and managing PFIC remains a challenge as there is lack of easy availability of genetic tests.

PFIC is divided into three types (types 1, 2 and 3) based on the genetic defect involved in bile transport. PFIC 1 and 2 typically are characterized by defect in bile acid excretion whereas PFIC 3 is associated with impaired phospholipid excretion. PFIC 1, also known as Byler disease is associated with defects in *ATP8B1* gene on chromosome 18 (18q21-22), which encodes for familial intrahepatic cholestasis 1 (FIC1) protein. Exact mechanism of cholestasis and other symptoms in PFIC1 is not fully elucidated. It is proposed to be due to impaired activity of farnesoid X receptor (FXR), a nuclear receptor related to regulation of metabolism of bile acids, resulting in down-regulation of bile salt exporter pump (BSEP) protein and upregulation of synthesis of bile acid in the hepatocytes.^{1,2} There is also an upregulation of apical sodium bile salt transporter (ASBT) in microvilli of small intestine resulting in increased ileal bile absorption.⁵ Down regulation of cystic fibrosis transmem-

brane conductance regulator (CFTR) in cholangiocytes of patients with PFIC1 has also been proposed.² Presence of ATP8B1 in the membrane of cells of small intestine, kidney and pancreas might explain extrahepatic man-

ifestations of PFIC1 like pancreatic insufficiency, sweat electrolyte abnormalities, diarrhea, short stature, epistaxis and sensorineural deafness. The intense pruritus involving the extremities and scalp results in marked thick-

Table 1. Laboratory parameters of the patient in last six months.

Parameters (normal values)	6 months ago	On presentation
Hb (11.5-14.5 mg%)	12.2 mg%	12.4 mg%
TLC (4000-12,000/cu mm)	5500 cu mm	4500 cu mm
Platelets (1.5 L-4.5 L/cu mm)	500,000 cu mm	450,000 cu mm
AST (0-50 U/L)	62 IU/L	65 IU/L
ALT (0-50 U/L)	55 IU/L	62 IU/L
TB (\leq 1.00 mg/dL)	2.5 mg/dL	1.9 mg/dL
DB (0.0-0.3 mg/dL)	1.5 mg/dL	1.4 mg/dL
ALP (149-369 U/L)	538 U/L	592 U/L
TP ($>$ 6.5 mg/dL)	7.5 mg%	7.2 mg%
Albumin (3-5 gm/dL)	4 mg%	3.9 mg%
PT (11-13 s)	13 s	14 s

Hb, hemoglobin; TLC, total leucocyte counts; AST, aspartate transaminase; ALT, alanine transaminase; ALP, alkaline phosphatase; TB, total bilirubin; DB, direct bilirubin; TP, total protein; PT, prothrombin time.

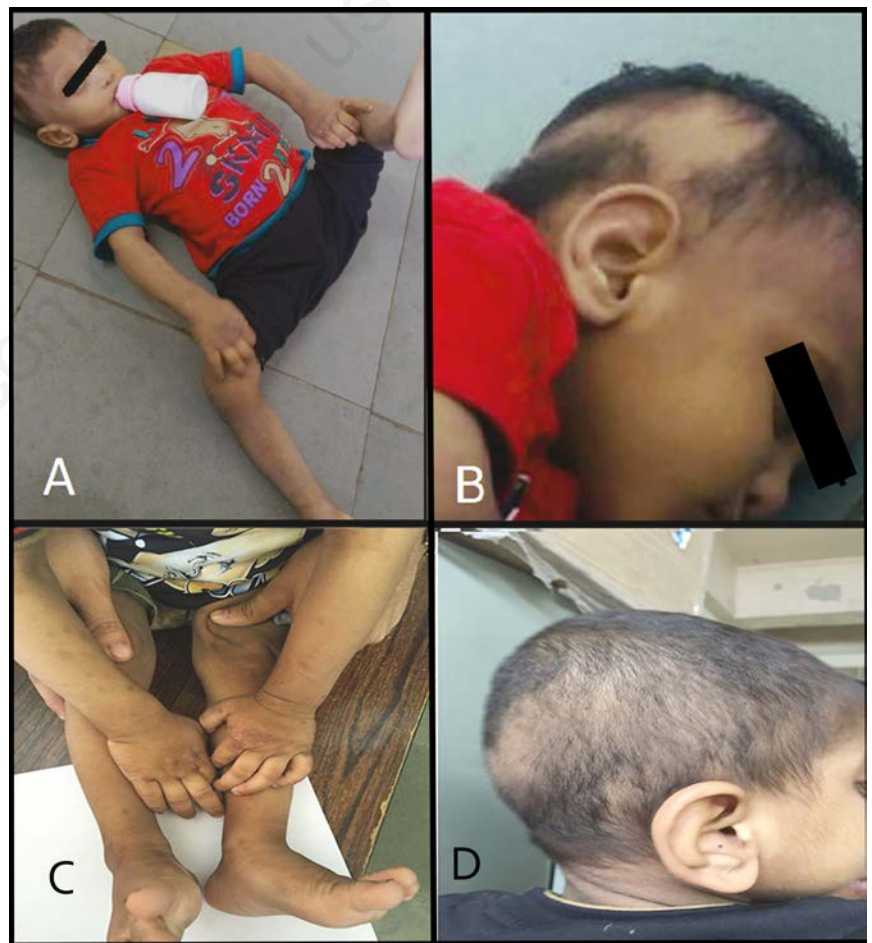

Figure 1. A) A restless child with intense itching, excoriated and dry skin; and B) a patch of hair loss on scalp before starting treatment. C) Significant improvement in skin texture with only few pigmented spots seen in both upper and lower limbs seen after two months of treatment; and D) recovering of alopecia after two months of treatment.

Table 2. Summarizing the case reports/case series of progressive familial intrahepatic cholestasis reported from India.

Case report/ Series	Age of onset (months) and sex	Presenting features	PFIC subtype	Method of diagnosis	Treatment
Ganesh <i>et al.</i> ⁹	6 months, boy	Persistent jaundice Pruritus, alopecia, growth failure,	PFIC I	Liver biopsy and electron microscopy	PIBD (cholecystojejunocolic anastomosis)
Sharma <i>et al.</i> ¹⁰	1 month, girl	Neonatal cholestasis	PFIC II	Liver biopsy and mutational analysis for ABCB 11 (done from outside India)	PEBD (cholecystoappendicostomy)
Koshy <i>et al.</i> ¹¹	30 months, male	Pruritus, jaundice	PFIC I/II	Liver biopsy	PEBD
Kaur <i>et al.</i> ¹² (series of seven patients)	6 months -36 months, 4 boys, 3 girls	Pruritus, jaundice in 3 patients Decompensated liver disease in 4 patients	PFIC I/II-3 patients PFIC II-2 patients PFIC III-2 patients	Liver biopsy and electron microscopy	Liver transplant in 3 patients Biliary diversion in 2 patients Medical therapy in 1 patient
Zaki <i>et al.</i> ¹³	8 months, girl	Pruritus, jaundice	PFIC III	Liver biopsy	Medical therapy
Present case	6 months, boy	Debilitating pruritus, alopecia, growth failure	PFIC I	Liver biopsy and electron microscopy	Medical therapy

PFIC, progressive familial intrahepatic cholestasis; PIBD, partial internal biliary drainage; PEBD, partial external biliary drainage.

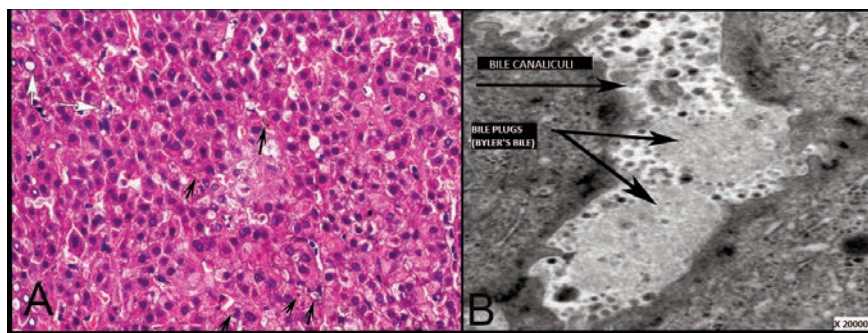


Figure 2. A) Hematoxylin and eosin stain section of the liver biopsy specimen depicting intrahepatic cholestasis (as shown by small black arrows) with hepatocytes showing feathery and hydropic changes (white arrows) without significant portal inflammation, suggestive of bland cholestasis. B) Electron microscopy picture of liver biopsy specimen demonstrating the bile canaliculi with coarse bile plugs suggestive of Byler's bile (black arrows).

ening, lichenification, excoriation, hyperpigmentation of skin, shiny nails and occasionally cicatricial alopecia.⁶ The weight and height is usually below normal centiles due to fat malabsorption. Cirrhosis with portal hypertension and decompensation develops earlier in the first year of life in PFIC type 2 as compared to early childhood in type 1.⁷

Our patient developed intense pruritus since the age of six months and jaundice since the age of one year. History of consanguinity in parents with evidence of intrahepatic cholestasis, predominant pruritus, normal GGT, raised serum bile acid level, bland cholestasis on biopsy suggested the diagnosis of PFIC 1 in our patient. Other factors that helped in distinguishing PFIC 1 from PFIC 2 in our patient included presence of growth failure, absence of evidence of portal hypertension, gallstones and only mild increase in aminotransferase levels. Liver biopsy also favored PFIC 1 as there was absence of giant cell hepatitis, significant portal inflammation and fibrosis all of which are seen more commonly in PFIC 2. Lastly

electron microscopy was the key in our patient demonstrating the characteristic granular bile (*O Byler's bile*) seen classically in PFIC 1 as compared to amorphous bile seen in PFIC 2.

Genetic testing is the gold standard for confirmation of diagnosis as prognosis and definitive management of patients differ between PFIC 1 and 2.⁸ Genetic testing involves DNA sequencing of the 27 coding exons and their splice junctions. Patients suspected to have PFIC 1 or 2 should undergo immunohistochemistry staining with BSEP protein. Those who are negative for BSEP staining should undergo mutational analysis for ABCB 11 (for PFIC 2), whereas those who are positive should undergo analysis for ATP8B1 (for PFIC 1). Unfortunately, none of these testing were available at our center. Literature search revealed only four case reports and one case series of seven patients of PFIC reported from India. Table 2 summarizes the presenting feature, mode of confirming the diagnosis and management strategies in each of them.⁹⁻¹³ Genetic analysis was possible in only one case

done from overseas. Four cases could not be differentiated between PFIC I or II. Biliary diversion was used in five patients for relieving jaundice and pruritus.⁸⁻¹¹ Medical therapy was successful in one patient. Three patients underwent live donor liver transplant for decompensated liver disease out of which one died.¹²

Our patient successfully responded to medical therapy comprising of UDCA, cholestyramine and rifampicin. There was no indication of biliary diversion at this stage as his pruritus had resolved and there was no significant jaundice. Liver transplant is indicated in patients with end stage liver disease or hepatocellular carcinoma or those with poor quality of life due to pruritus despite medical therapy and biliary diversion. Liver transplant has guarded prognosis in patients with PFIC I if extrahepatic manifestations are present at the onset.³ Recurrence of PFIC after a successful Liver transplant is a possibility due to alloimmunization of recipient against the effected protein (FIC 1, MDR 3 or BSEP).¹⁴

Prognosis in PFIC is variable. A series of 62 children with PFIC I/II showed that 87 % patients were alive at median age of 10.5 years with therapy.¹⁵ In another series of 33 patients with PFIC I/II only seven patients were older than 16 years on their last follow up.¹⁵ Genetic testing as well as genetic counselling of parents and prenatal diagnosis of PFIC is still at a premature stage in India whereas it has become a standard of care in managing patients of PFIC in the West.¹⁶

Conclusions

Early recognition and prompt referral to higher center for biliary diversion and/or liver

transplant in cases of failure of medical therapy is crucial in managing PFIC patients. More reports and long term follow up data on PFIC is required from India.

References

- Jacquemin E. Progressive familial intrahepatic cholestasis. *Clin Res Hepatol Gastroenterol* 2012;36:S26-35.
- Hori T, Nguyen JH, Uemoto S. Progressive familial intrahepatic cholestasis. *Hepatobiliary Pancreat Dis Int* 2010;9:570-8.
- Srivastava A. Progressive familial intrahepatic cholestasis. *J Clin Exp Hepatol* 2014; 4:25-36.
- Clayton RJ, Iber FL, Ruebner BH, Me Kusick VA. Fatal familial intrahepatic cholestasis in Amish kindred. *J Paediatr* 1965;67:1025-28.
- Martinez-Fernandez P, Hierro L, Jara P, Alvarez L. Knockdown of ATP8B1 expression leads to specific downregulation of the bile acid sensor FXR in HepG2 cells; effect of FXR agonist GW4064. *Am J Physiol Gastrointest Liver Physiol* 2009; 296:G1119-29.
- Doi BC, Phla KB, Lee BL, et al. Lichenification and enlargement of hands and feet: A sign of progressive familial intrahepatic cholestasis with normal gamma glutamyl transpeptidase. *J Pediatr Gastroenterol Nutr* 2001;32:219-23.
- Bull LN, Carlton VE, Stricker NL, et al. Genetic and morphological findings in progressive familial intrahepatic cholestasis (Byler disease [PFIC 1] and Byler syndrome: Evidence for heterogeneity. *Hepatology* 1997;26:155-64.
- Liu C, Aronow BJ, Jegga AG, et al. Novel resequencing chip customized to diagnose mutations in patients with inherited syndromes of intrahepatic cholestasis. *Gastroenterology*. 2007;132:119-26.
- Ganesh R, Suresh N, Sathiyasekaran M, Ramachandran P. Partial internal biliary diversion: A solution for intractable pruritus in progressive familial intrahepatic cholestasis type 1. *Saudi J Gastroenterol* 2011;17:212-4.
- Sharma D, Shah UH, Sibal A, Chowdhary SK. Cholecystoappendicostomy for progressive familial intrahepatic cholestasis. *Indian Pediatr* 2010;47:626-8.
- Koshy A, Ramesh H, Mahadevan P, et al. Progressive familial intrahepatic cholestasis: a case with improvement in liver tests and growth following partial external biliary diversion. *Indian J Gastroenterol* 2009;28:107-8.
- Kaur S, Sharma D, Wadhwa N, et al. Therapeutic interventions in progressive familial intrahepatic cholestasis: experience from a tertiary care centre in north India. *Indian J Pediatr* 2012;79:270-3.
- Zaki SA, Shanbag P, Amarapurkar A. PFIC type III in infant presenting as acute liver cell failure. *Indian J Pathol Microbiol* 2010;53:334-6.
- Maggiore G, Gonzales E, Sciveres M, et al. Relapsing features of bile salt export pump deficiency after liver transplantation in two patients with progressive familial intrahepatic cholestasis type 2. *J Hepatol* 2010;53:981-6.
- Davit-Spraul A, Fabre M, Branchereau S, et al. ATP8B1 and ABCB11 analysis in 62 children with normal gamma-glutamyl transferase progressive familial intrahepatic cholestasis (PFIC): phenotypic differences between PFIC1 and PFIC2 and natural history. *Hepatology* 2010;51:1645-55.
- Chen ST, Chen HL, Su YN, et al. Prenatal diagnosis of progressive familial intrahepatic cholestasis type 2. *J Gastroenterol Hepatol* 2008;23:1390-3.

Non commercial use only