

Bifid mandibular canal: a rare or underestimated entity?

Ibrahim Nasseh,¹ Georges Aoun²

¹Department of Dentomaxillofacial Radiology and Imaging; and ²Department of Oral Pathology and Diagnosis, Lebanese University, Beirut, Lebanon

Abstract

One of the rare anatomical variations that can be of significant importance for the dentist is the bifid mandibular canal. Many complications can occur from this condition such as failure of anesthesia when performing inferior alveolar nerve block, difficulties during the surgical extraction of the third mandibular molar, and during implants placement. Therefore, good knowledge of this condition is essential. In this report, we describe the radiographic finding of a unilateral bifid mandibular canal.

Introduction

The mandibular canal (MC) transmits the inferior alveolar nerve (a branch of the mandibular nerve which is the third division of the trigeminal nerve) and the inferior alveolar artery and vein.

The inferior alveolar nerve supplies the mandibular teeth and gives off the mental nerve, which exits the MC through the mental foramen.

Knowledge of the anatomy and location of the MC are essential for successful procedures in the region such as inferior alveolar nerve block, surgical dental extractions especially wisdom teeth, implants placement, *etc.*¹

Anatomical variations of the MC, mostly bifid,^{2,4} and more rarely trifid,⁵ have been reported by many authors using different radiographic technologies [panoramic, computed tomography (CT) and cone-beam computed tomography (CBCT)].²⁻⁴

This report describes a case of a unilateral bifid MC (BMC) suspected by a panoramic radiograph and confirmed by a CBCT prior to a dental treatment.

Case Report

A 22-year old male presented to our office for extraction of his wisdom teeth.

On the panoramic, #18 was absent, while

#28, #38 and #48 were impacted with mesio-angulated inclination (Figure 1).

The apices of #38 and #48 were superimposed on the left and right image of the MC and a BMC was suspected at the left side. A CBCT was requested for further assessment.

On the CBCT examination, and after drawing the canal on both sides, the following were noted: i) on the right side: the MC is located lingual to the root of the #48, in close relationship with the distal root (Figure 2); ii) on the left side: at the exit of the mandibular foramen, appears the usual track of the MC, but distal to him, appears another thinner canal that goes more inferior, closer to the inferior border of the mandible, and join the principal canal at the level of the distal root of #37 (Figures 3 and 4).

At the level of #38, the MC is located lingual to it, in close relationship with its distal and mesial root.

Discussion

BMC was evaluated by many authors by means of different radiographic techniques.

Panoramic radiographs were used by Nortje *et al.* who found an incidence of 0.9% of BMC (33/3612),² and by Langlais *et al.* with 0.96% (57/6000).³

In the same way, studies conducted by Grover and Lorton, Zografos *et al.*, and Sanchiz *et al.* found that the prevalence of BMC was respectively 0.08% (4/5000),⁶ 0.4% (3/700),⁷ and 0.35% (7/2012).⁸

A higher incidence was reported by Durst and Snow [8.3% (85/1024)].⁹

Nowadays, with the technological improvement of the imaging techniques such as CBCT, more details are provided and consequently better evaluation. Thus, many studies propose that the incidence of BMC is underestimated with the use of panoramic radiographs alone.^{9,10}

Kuribayashi *et al.*, consider that the incidence of BMC may be superior when using CBCT, since panoramic radiographs are not adequate to detect all canals especially narrow ones. In their study, they reported the prevalence of BMC to be as 15.6% (47/301).⁴

These findings were consistent with the ones of Klinge *et al.*, who concluded in their study performed on cadavers that panoramic images were unsuccessful to identify the MC in 36.1% of cases,¹⁰ and Bogdán *et al.*, who noticed that among their specimens, only 0.2% of BMCs were visible on panoramic radiographs while 19.6% were detectable on dry mandibles.⁵

On the other hand, on panoramic images, some anatomical structures may mimic BMCs such as the groove of the mylohyoid nerve

Correspondence: Georges Aoun, Department of Oral Pathology and Diagnosis, Faculty of Dentistry, Lebanese University, Beirut, Lebanon. E-mail: aoungorges@yahoo.com

Key words: Anatomical variation; bifid mandibular canal; cone-beam computed tomography.

Contributions: the authors contributed equally.

Conflict of interest: the authors declare no potential conflict of interest.

Received for publication: 18 August 2016.

Accepted for publication: 22 September 2016.

This work is licensed under a Creative Commons Attribution NonCommercial 4.0 License (CC BY-NC 4.0).

©Copyright I. Nasseh and G. Aoun, 2016
Licensee PAGEPress, Italy
Clinics and Practice 2016; 6:881
doi:10.4081/cp.2016.881

located on the deep internal surface of the mandible ramus,^{8,11} or some intra-bony dense trabecular formations.¹²

This being said, even if routine panoramic radiographs prior to many dental and oral procedures in the region of the MC are largely rec-

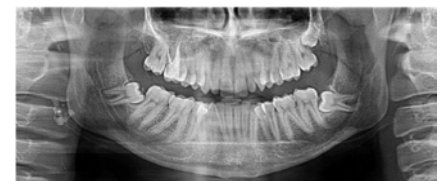

Figure 1. Initial panoramic view at first consultation.

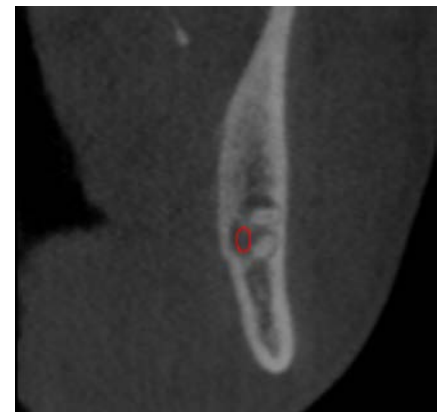


Figure 2. Cross sectional cut showing the location of the mandibular canal.

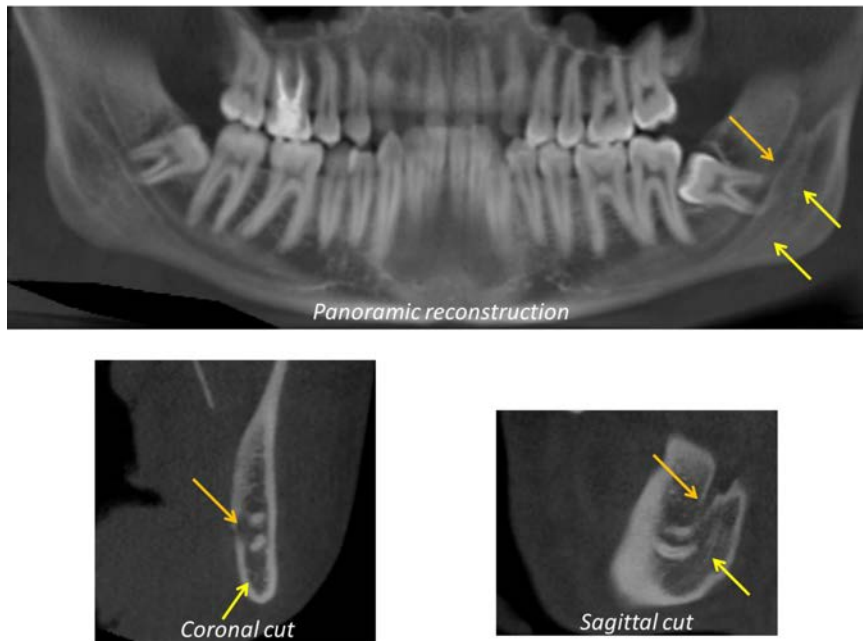


Figure 3. The left double mandibular canal as seen on the cone-beam computed tomography panoramic reconstruction, coronal and sagittal cuts.

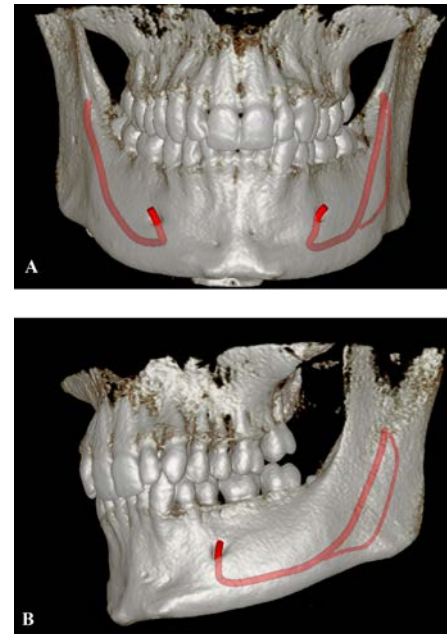


Figure 4. 3D-volume rendering: A) frontal view; B) lateral left view.

ommended, they have limitations in exhibiting intra-osseous structures consequently when used to assess the existence and the configuration of BMCs. Contrariwise, CBCT is considered more accurate for differentiating true from false BMCs.^{4,12}

Concerning the types of BMCs, many classifications have been suggested by different authors among others Nortjé *et al.*,² Naitoh *et al.*,¹³ and Langlais *et al.*³ whose classification remains the most cited in the literature.¹⁴

The latter is divided into four types according to their locations and shapes (Table 1).

According to many authors, the BMC type extending to the third molar region is the most frequent.¹⁵⁻¹⁷

We believe our present case is still a rare variation.

Conclusions

Although considered a rare anatomical variation, BMC may be found in each patient and must be assessed adequately.

Technological improvement of imaging techniques has provided alternatives for complete and precise evaluations. Among these techniques is CBCT, which provides images in the three planes, offering better information about the MC and the detection/confirmation of BMCs thereby preventing probable complications.

Table 1. Bifid mandibular canal classification according to Langlais *et al.*

Type of BMC	Description
Type 1	Unilateral extending to the region of the third molar Bilateral extending to the region of the third molar
Type 2	Unilateral extending along the main canal and then coming together in the mandibular rami Unilateral extending along the main canal and then coming together in the mandibular body Bilateral extending along the main canal and then coming together in the mandibular rami Bilateral extending along the main canal and then coming together in the mandibular body
Type 3	Combination between types 1 and 2
Type 4	Two canals from two distinct origins, and then joining to form a single, large MC

BMC, bifid mandibular canal.

References

- Naitoh M, Hiraiwa Y, Aimiya H, et al. Bifid mandibular canal in Japanese. *Implant Dent* 2007;16: 24-32.
- Nortje CJ, Farmen AG, Grotepass FW. Variations in the normal anatomy of the inferior dental (mandibular) canal: a retrospective study of panoramic radiographs from 3612 routine dental patients. *Br J Oral Surg* 1977;15:55-63.
- Langlais RP, Broadus R, Glass BJ. Bifid mandibular canals in panoramic radiographs. *J Am Dent Assoc* 1985;110:923-6.
- Kuribayashi A, Watanabe H, Imaizumi A, et al. Bifid mandibular canals: cone beam computed tomography evaluation. *Dentomaxillofac Radiol* 2010;39:235-9.
- Bogdán S, Pataky L, Barabás J, et al. Atypical courses of the mandibular canal: comparative examination of dry mandibles and x-rays. *J Craniofac Surg* 2006;17:487-91.
- Grover PS, Lorton L. Bifid mandibular nerve as a possible cause of inadequate anaesthesia in the mandible. *J Oral Maxillofac Surg* 1983;41:177-9.
- Zografos J, Kolokoudias M, Papadakis E. The types of mandibular canal. *Hell Period Stomat Gnathopathoprosopike Cheir* 1990;5:17-20.
- Sanchis JM, Peñarrocha M, Soler F. Bifid mandibular canal. *J Oral Maxillofac Surg* 2003;61:422-4.
- Durst JH, Snow JE. Multiple mandibular canals: oddities or fairly common anomalies? *Oral Surg Oral Med Oral Pathol* 1980;49:272-3.
- Klinge B, Petersson A, Maly P. Location of the mandibular canal: comparison of macroscopic findings, conventional radiography, and computed tomography. *Int J*

- Oral Maxillofac Implants 1989;4:327-32.
11. Auluck A, Pai KM, Shetty C. Pseudo bifid mandibular canal. Dentomaxillofac Radiol 2005;34:387-8.
 12. Kim MS, Yoon SJ, Park HW, et al. A false presence of bifid mandibular canals in panoramic radiographs. Dentomaxillofac Radiol 2011;40:434-8.
 13. Naitoh M, Hiraiva Y, Aimiya H, Arijji E. Observation of bifid mandibular canal using cone beam computerized tomography. Int J Oral Maxillofac Implants 2009;24:155-9.
 14. Rossi PM, Brücker MR, Rockenbach MIB. Bifid mandibular canals: panoramic radiographic analysis. Rev Cienc Med 2009;18:99-104.
 15. Fu E, Peng M, Chiang CY, et al. Bifid mandibular canals and the factors associated with their presence: a medical computed tomography evaluation in a Taiwanese population. Clin Oral Implants Res 2014;25:e64-7.
 16. al Jasser NM, Nwoku AL. Radiographic study of the mental foramen in a selected Saudi population. Dentomaxillofac Radiol 1998;27:341-3.
 17. Correr GM, Iwanko D, Leonardi DP, et al. Classification of bifid mandibular canals using cone beam computed tomography. Braz Oral Res 2013;27:510-6.

Non commercial use only