

# Traumatic pseudoaneurysm of the superficial temporal artery

Suvy Manuel, Deepti Simon,  
Eldhose K. George, Raghava B. Naik  
Department of Oral and Maxillofacial  
Surgery, Government Dental College,  
Trivandrum, Kerala, India

## Abstract

Aneurysms of the superficial temporal artery are relatively rare vascular complications following trauma. Two cases of pseudoaneurysm of the anterior branch of the superficial temporal artery, subjected to blunt maxillofacial trauma are presented here. The first case was treated by surgical resection and the second was cured by application of continuous pressure. The review of the English literature has also been included. An awareness of these vascular injuries, despite their infrequency, is necessary to facilitate early diagnosis, proper investigation and prompt treatment.

## Introduction

The branches of external carotid artery are protected from injury in most locations by an adequate buffer of soft tissue. On occasion, the vessels approach the surface to cross bone structures and in these key areas they become vulnerable to blunt trauma. The facial, superficial temporal and terminal branches of the internal maxillary artery are the branches most often affected via this mechanism of injury.<sup>1</sup> We present two cases illustrating the highlights of clinical examination, diagnostic modalities and management of Superficial Temporal Artery (STA) aneurysm.

## Case Report #1

A 29-year-old healthy male reported to our unit following road traffic accident. He had sustained generalized abrasions and contusion on left side of face with evidence of left zygomatic arch fracture. A computed tomography (CT) scan of the head revealed no evidence of neurotrauma or associated skull bone fractures. Though there was no trismus, a depression on midpoint of the left arch was noticed. The fracture was reduced by an intra oral approach. Eight weeks following trauma, patient reported with a swelling in the left temporal region, which had seen gradually

increasing in size. Examination revealed a pulsatile swelling of 2×1.5 cm size, spherical, soft, mobile, and non-tender with well-defined borders. The swelling was situated posterio-superior to the left lateral orbital rim (Figure 1).

The mass was noted to be within the course of frontal branch of the left STA and the pulsations disappeared, with pressure on the proximal portion of the artery. The lesion was suspected to be vascular in origin and an angiography was performed. The left common carotid artery injection showed a blushing at the terminal branches of the left anterior STA (Figure 2). A selective internal carotid artery injection revealed no relevant findings.

With the provisional diagnosis of a post traumatic false aneurysm of the anterior branch of the left STA, the lesion was excised under general anesthesia. Incision was given within the hairline parallel to the anterior branch of STA. The aneurysm presented as a bluish tinged ovoid swelling about 2×1.5 cm diameter and approximately 2 cm behind the lateral orbital rim. The aneurysmal sac was mobilized by blunt dissection, the feeding vessel was ligated and the lesion excised (Figure 3).

Histopathology depicted an artery with an aneurysm. The dilated aneurysmal area showed thrombosis, focal hemorrhage and inflammatory changes in the vessel wall. The arterial wall showed evidence of chronic inflammation, with dissection and hemorrhage. The lumen contained an organizing thrombus (Figure 4). The findings were consistent with that of a false arterial aneurysm.

## Case Report #2

A 25-year-old man complained of a throbbing painless mass, 0.5×0.5 cm on the left temple, 27 days after a fall. The left periorbital region showed healing abrasions sustained during the incident (Figure 5). A bruit was audible over the mass, was compressible and was located in the frontal division of the superficial temporal artery. The mass was clinically diagnosed as a post-traumatic aneurysm of the STA. The patient was apprehensive about surgery and other interventional radiological procedures; hence it was decided to try application of continuous pressure by means of a pressure dressing. The swelling gradually reduced in size and had resolved completely by the end of 5 weeks.

## Discussion

An aneurysm is a sac filled with blood in direct communication with the interior of an artery. A true aneurysm is due to local dilata-

Correspondence: Manuel Suvy, The Oral Surgery Practice, Temple Lane, Sreekariyam PO, Trivandrum 695017, Kerala, India.  
Tel. +91.471 2595099.  
E-mail: manuelsuvy@yahoo.com

Key words: pseudoaneurysm, superficial temporal artery, maxillofacial trauma.

Received for publication: 24 December 2011.

Revision received: 5 February 2012.

Accepted for publication: 9 February 2012.

This work is licensed under a Creative Commons Attribution NonCommercial 3.0 License (CC BY-NC 3.0).

©Copyright S. Manuel et al., 2012  
Licensee PAGEPress srl, Italy  
Clinics and Practice 2012; 2:e34  
doi:10.4081/cp.2012.e34

tion of the artery whereas a false aneurysm is a sac with walls formed of condensed connective tissue, which communicates, with the lumen of the artery through an aperture in its wall.<sup>2</sup>

Aneurysms of the facial vasculature have been reported since the mid-seventeenth century from a variety of accidental and iatrogenic injuries. Approximately 400 cases of facial aneurysm have been documented in world literature, of which 340 involve the superficial temporal artery. The first reported case of a temporal artery aneurysm was by Thomas Bartholin in 1740.<sup>3</sup> Bloodletting, dueling, sporting injuries, temperomandibular joint surgeries, hair transplantation and neurosurgical procedures have been implicated in its etiology. An extensive review of superficial temporal artery (STA) pseudoaneurysms was elaborated by Evans *et al.* in 2003.<sup>4</sup> Pieck *et al.* stated that 75% were secondary to blunt trauma, 80% occurred in males, the average age of the patient was 33 years and most lesions developed within 2-6 weeks of injury. The size of the aneurysms varied from 5 mm to 4 cm.<sup>5</sup> Both the cases discussed above seem to be due to blunt trauma.

The typical complaints are headache, dizziness, audible pulsations, ear discomfort and cosmetic deformity. In some cases the pulsations may be absent or too weak to be palpated, masked by hematoma and/or thrombus formation. Compression of the superficial temporal artery near the external auditory meatus can eliminate the pulsations and bruit.<sup>3</sup> Both the patients presented here, were primarily concerned about cosmesis.

Pseudoaneurysms can arise in the forehead and scalp as a result of blunt traumatic impingement of the superficial temporal artery against the calvarium. The anterior branch of the artery is more vulnerable, because it courses over the

frontal osseous ridge in the galea aponeurotica, formed by the fusion line of the deep and superficial temporalis muscle fascia. This dense facial investment has a tethering effect in the gap between the temporalis and frontalis muscles and prevents the artery from displacing laterally in response to traumatic forces.<sup>6</sup>

The lesion develops due to a localized laceration of the arterial wall with maintenance of blood flow. The leakage of blood produces a hematoma and continues till the pressure within it equals arterial pressure. After several weeks central liquefaction occurs producing a cavity lined on the inside by pseudointima and on the outside by connective tissue. As the hematoma liquefies, the aneurysm begins to pulsate and enlarge.<sup>7</sup>

Diagnosis is made by observation of a mass, usually pulsatile in the region of STA. A thrill or systolic bruit may be present, depending on the amount of clot and the blood flow through the aneurysm. Both the reported cases demonstrated pulsatility. A continuous thrill or bruit, often with a systolic accentuation is more likely to be associated with arteriovenous fistula; those of a false aneurysm will be systolic only. Differential diagnosis includes simple hematoma, lipoma, epidermal inclusion cyst, abscess and arteriovenous fistula (AVF). AVF has a continuous thrill on palpation, whereas the other lesions are non-pulsatile.<sup>8</sup>

The most accurate non-invasive modality to aid in the diagnosis is a duplex ultrasound scan of the lesion. Arteriography helps in the diagnosis and clarifies the feeding vessel. Doppler scan, CT angiography and magnetic resonance imaging are other useful investigations.<sup>8</sup> However the diagnosis is confirmed by histopathology. Our provisional diagnosis made on clinical and radiological grounds was proven true based on the post excisional histopathological findings that the lesion was a pseudoaneurysm in the first case. Arteriography defined the extent of the lesion and surrounding area. In the second case the diagnosis was based only on the clinical picture. Complications can range from hemorrhage following rupture of the aneurysm, compression of adjacent nerves and release of embolic thrombi, with risk to the circulating system of the brain.<sup>8</sup>

Isaacson *et al.* in 2004 reviewed the treatment options of pseudoaneurysms of STA.<sup>9</sup> Surgical resection, ligation without resection, intravascular sclerosis, endovascular coil embolization, ultrasound-guided compression, and percutaneous thrombin embolization have all been used to treat this lesion. Surgical resection cures pseudoaneurysms in most cases. The frontal and zygomatic branches of the facial nerve are at risk during this procedure. The objective in treatment of pseudoaneurysms is to gain proximal and distal control of the damaged vessel. In areas where surgical

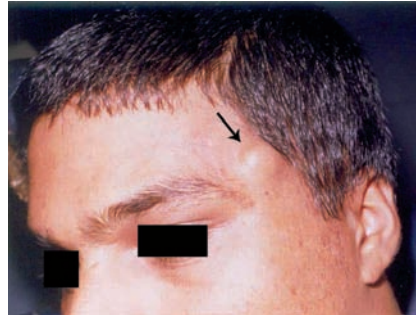access is difficult, selective embolization offers a safer option, due to decreased risk of bleeding and revascularization of the lesion by collateral circulation.<sup>7</sup> Local sclerosis is effective but may cause distal tissue necrosis. Coil embolization is effective and leaves no facial scar but carries small risk of stroke, lower extremity ischemia and groin pseudoaneurysm.

An 1861 article in *The Lancet* describes a medical student, who had complete resolution

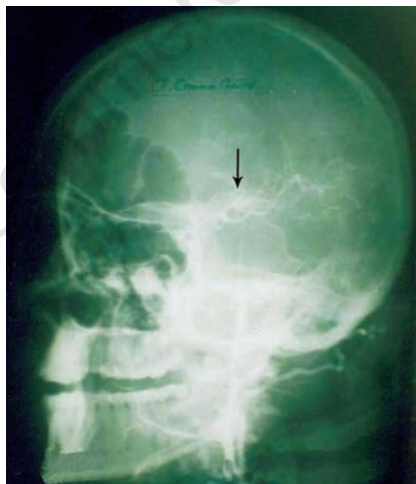of his aneurysm, by applying pressure to the region with his hand while engaged in his studies.<sup>8</sup> Kopelman *et al* report a case that was obliterated by continuous local pressure. They opine that application of local pressure is the best measure for preventing the development of pseudoaneurysm following blunt temporal trauma.<sup>10</sup> Fox *et al.* 1994 tried using finger compression for three 20 min intervals, and

did not obtain success. The lesion was successfully treated surgically.<sup>8</sup> Lemonnier *et al.* in 2010 report a case where ultrasound guided compression was used as a treatment modality which failed, and surgery was resorted to.<sup>11</sup> Our second case responded favorably to the application of local pressure, possibly due to its small size.

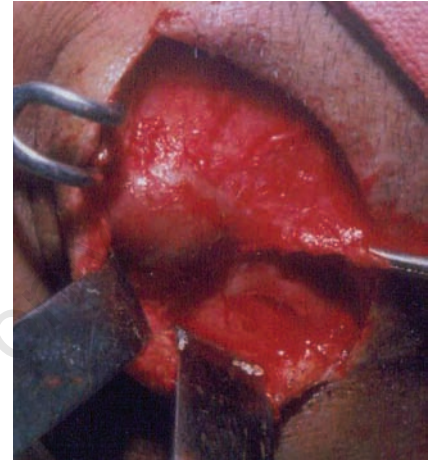
Given the relatively long and exposed course of the superficial temporal artery over the temporal bone, STA aneurysms are less than 1% of



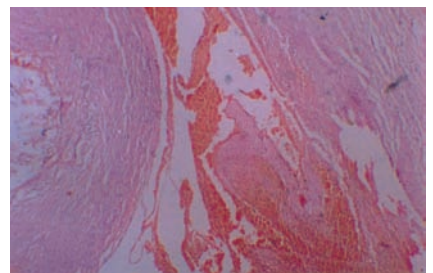
**Figure 1.** Clinical photograph showing the aneurysm, postero superior to the lateral orbital rim (black arrow).



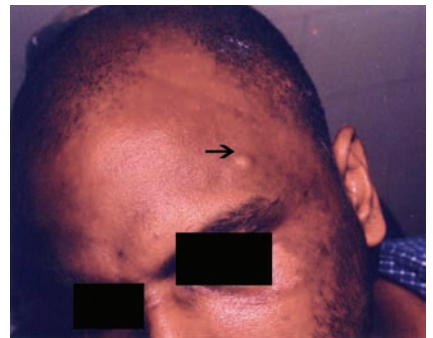**Figure 2.** Left common carotid angiogram showing the aneurysm in the filling stage (black arrow).



**Figure 3.** Intraoperative view showing the saccular aneurysmal mass.



**Figure 4.** Section shows the dilated aneurysmal area with thrombosis. Focal hemorrhage and inflammatory changes are noted in the vessel wall (H&E stain, original magnification  $\times 10$ ).



**Figure 5.** Clinical photograph showing the aneurysm above the left eyebrow.

all reported cases.<sup>3</sup> They may intrigue the clinician in the form of a hematoma, cyst or lipoma, thus making it imperative for the medical fraternity to be familiar with the clinical presentation, diagnostic modalities and treatment for this rare vascular entity.

## References

1. Conner WC 3rd, Rohrich RJ, Pollock RA. Traumatic aneurysms of the face and temple: a patient report and literature review, 1644 to 1998. *Ann Plast Surg* 1998;41:321-6.
2. Grainger RG, Allison DJ, Adam A, Dixon AK (Eds). *Grainger and Allison's diagnostic radiology: a textbook of medical imaging*. Vol. III, third edition. London: Churchill Livingstone; 1997. p. 2375.
3. Han K, Borah GL. Pseudoaneurysm of the anterior superficial temporal artery. *Ann Plast Surg* 1996;37:650-3.
4. Evans CC, Larson MJ, Eichhorn PJ, Taylor RS. Traumatic pseudoaneurysm of the superficial temporal artery: two cases and review of the literature. *J Am Acad Dermatol* 2003;49 Suppl:S286-8.
5. Peick AL, Nichols WK, Curtis JJ, Silver D. Aneurysms and pseudoaneurysms of the superficial temporal artery caused by trauma. *J Vasc Surg* 1988;8:606-10.
6. Cremonese JC, Grosh JD. Traumatic aneurysms of the superficial temporal artery. *J Trauma* 1980;20:968-8.
7. Gerbino G, Rocchia F, Grosso M, Regge D. Pseudoaneurysm of the internal maxillary artery and Frey's syndrome after blunt facial trauma. *J Oral Maxillofac Surg* 1997; 55:1485-90.
8. Fox JT, Cordts PR, Gwinn BC. Traumatic aneurysm of the superficial temporal artery: a case report. *J Trauma* 1994;36: 562-4.
9. Isaacson G, Kochan PS, Kochan JP. Pseudoaneurysms of the superficial temporal artery: treatment options. *Laryngoscope* 2004;114:1000-4.
10. Kopelman D, Nitecki S, Hashmonai M. [Posttraumatic superficial temporal artery pseudoaneurysm.] *Harefuah* 1993;125: 466-7, 495. [Article in Hebrew].
11. Lemonnier C, Melki J, Benadiba L, Janvresse A. [Traumatic pseudoaneurysm of the superficial temporal artery: a case report.] *J Mal Vasc* 2010;35:263-5. [Article in French].