

Primary hyperparathyroidism with rare presentation as multiple brown tumours

Smit Doshi,¹ Arti Vadi,¹ Amit Mahajan,² Tapan Nagpal¹

¹Department of ENT and ²Department of Oral and Maxillofacial Surgery, S.B.K.S. Medical institute and research center, Waghodia, Vadodara, India

Abstract

We present a case of primary hyperparathyroidism with an uncommon presentation as multiple brown tumours, which may easily be mistaken for a primary bone neoplasm. A brief literature review and its clinical and surgical management are also discussed here.

Introduction

Hyperparathyroidism (HPT) is a disease in which there may be a complex of biochemical, anatomic and clinical abnormalities resulting from increased secretion of parathyroid hormone (PTH). Hyperparathyroidism may be primary due to idiopathic hyperplasia, which involves all four glands, or parathyroid adenoma, which is isolated involving only one gland, or as a part of Multiple Endocrine Neoplasia Syndrome¹ with resultant hypercalcemia. Secondary hyperparathyroidism¹ is usually secondary to calcium malabsorption and renal calcium loss due to chronic renal failure. Tertiary hyperparathyroidism¹ is due to acquired abnormalities of the parathyroid glands in long standing cases of hyperparathyroidism and chronic renal failure due to deficient response to parathyroid hormone at the level of the receptor in kidney (renal resistance). A fourth type occurs due to ectopic hyperparathyroidism in patient with malignancy. The classical *brown tumour* of hyperparathyroidism is an expansile osteolytic lesion resulting from excess osteoclast activity which can localize anywhere in the skeleton, the preferential locations being the head bones (particularly the mandible),² and the ends of long bones and ribs.³ However it has become increasingly rare to find multiple focal areas of demineralization of the skull; or brown tumour (osteitis fibrosa cystica) as part of the classic manifestation of the hyperparathyroid bone disease and it may be mistaken for primary skeletal neoplasms. Brown tumours are found in primary hyperparathyroidism but uncommon in secondary HPT⁴ and

extremely rare in normocalcemic hyperparathyroid patients.⁵

Case Report

A 30-year-old female presented with multiple swellings over different areas of body since 3 months, which followed after pregnancy. There was no other associated complaints or any significant family history. On examination there were multiple bony swellings present as follows: i) hard and mildly tender swelling in the right side body of mandible; ii) hard, nontender swelling present in left frontal region; iii) hard and nontender swelling present below the left knee joint. Radiological evaluation of the above areas revealed an osteolytic lesion at all sites (Figures 1, 2, 3). Her serological investigation - serum alkaline phosphate - 1080 U/L (normal 245-770 U/L) was also suggestive of increased osteoclastic activity. Serum calcium was 10.2 mg/dL (normal range- 9 to 11 mg/dL) and serum phosphorous was 2.1 mg/dL (normal range 2 to 4 mg/dL) raising the possibility of hyperparathyroidism, which was confirmed by a markedly elevated assay of serum PTH [>1900 pg/mL (normal: 11.1-79.5 pg/mL)]. All other routine blood investigations were normal. Ultrasonography neck (Figure 4) revealed presence of *hypo echoic lesion of size 21x10x11 mm on posterior-inferior aspect of left lobe of thyroid gland* (clinical examination of neck did not reveal any abnormal swelling or fullness).

A whole body computerized scans for complete skeletal survey revealed *multiple lytic expansile lesions involving whole skeleton and increase in size of parathyroid glands on left side* (Figure 5). The typical salt and pepper appearance on skull radiology and periarticular osteopenia on radiology of the hands was not very obvious.

The patient was operated under general anaesthesia with Inj. Methylene Blue being given at the dose of 7.5 mg/kg body weight as an intravenous infusion in 5% Dextrose 1 h prior to surgery (Methylene Blue is preferentially concentrated in the parathyroid which helps in easy localization). The left inferior parathyroid was found enlarged consistent with the Ultrasonography findings located along the branch of left inferior thyroid artery (Figure 6). It was carefully dissected from the left recurrent laryngeal nerve. Histo-pathology revealed it to be a parathyroid chief cell adenoma. Post-operatively both vocal cords were mobile and patient had an uneventful recovery. The patient was given a slow intravenous infusion of calcium gluconate after 24 h postoperatively and then put on oral calcium with active Vitamin D3 (calcitriol) to tide over the temporary hypocalcemia with the consequent tetany

Correspondence: Tapan Nagpal, Department of ENT, S.B.K.S. Medical institute and research center, Waghodia, Vadodara, India.
E-mail: tjpnagpal@rediffmail.com

Key words: hyperparathyroidism, brown tumour, osteitis fibrosa cystica, parathyroidectomy.

Conflict of interests: the authors declare no potential conflict of interests.

Received for publication: 18 January 2012.

Revision received: 23 February 2012.

Accepted for publication: 1 March 2012.

This work is licensed under a Creative Commons Attribution NonCommercial 3.0 License (CC BY-NC 3.0).

©Copyright S. Doshi et al., 2012
Licensee PAGEPress, Italy
Clinics and Practice 2012; 2:e48
doi:10.4081/cp.2012.e48

that may occur after removal of the parathyroid tumour due to suppression of normal parathyroid activity by the tumour. The parathyroid assay done post-operatively was now within normal range (23.5 pg/mL). Post-operatively in the third week the patient required a single parenteral supplementation of calcium gluconate and also magnesium sulphate to correct the hypocalcaemia and hypomagnesa that developed due to inadequate oral intake and depleted body stores of calcium and magnesium due to previously long standing hyperparathyroid disease. The patient was counseled regarding long-term oral calcium and magnesium supplementation post-operatively to re-build the depleted body stores.

Discussion

For unknown reasons hyperparathyroidism tends to present either with bone disease or with renal stones but never both.¹ It is more common in the female gender with the majority of cases in the third to fifth decade¹ as in our case.

Skeletal involvement in classical primary hyperparathyroidism reflects a striking increase in osteoclastic bone resorption and is accompanied by a cellular repair process that results in the accumulation of fibrillar stroma and connective tissue cells along with multinucleated giant cells and spicules of osteoid deposits. Thus the classical *brown tumor* of hyperparathyroidism is a collection of osteoclasts mixed with innocuous spindle cells and poorly mineralized woven bone.⁶ Even though the *brown tumor* can localize anywhere in the

skeleton, the preferential locations are the head bones (particularly the mandible),² and the ends of long bones and ribs.³ The rarity of multiple such lesions led us primarily to the differential diagnosis of fibrous dysplasia or less commonly a metastatic lesion. However the characteristic feature as post-operatively observed in our case was the haemorrhage and haemosiderin deposits⁷ which impart the brownish colour and hence the term. Treatment of brown tumour is dependent on the treatment of hyperparathyroidism. A majority of these lesions may disappear with the removal of the parathyroid pathology. It's generally accepted that treatment of brown tumor should start with treatment of underlying HPT and if persisted after this primary treatment, enucleation and curettage should be added especially if the lesion results in some functional problems.⁸ Resection is carried out in the majority of cases only to achieve a definitive diagnosis.

Primary hyperparathyroidism can be divided pathologically into adenomas (85%), hyperplasia (15%) and carcinomas (<1%).¹ Histologically distinction between adenomas and hyperplasia is virtually impossible with an increased cell to fat ratio in both. Adenomas involve only one gland as in our case (left inferior parathyroid). Double adenomas are rare (5% cases).¹ The major areas of debate surrounding primary hyperparathyroidism include: i) differentiation between adenomas and hyperplasia; ii) whether medical therapy in mild cases of primary hyperthyroidism is appropriate; iii) value of preoperative localization studies; iv) unilateral versus bilateral neck dissection as a surgical approach.

Melton⁹ concluded that long term medical therapy with calcitonin and bisphosphonates to reduce calcium level was costly and possible only in few cases of mild primary hyperparathyroidism with reversal of symptoms and bone density loss. 90-95% of adenomas can be found at neck exploration.¹⁰ Hence preoperative localization techniques like Thallium-Techetium subtraction scan, Ultrasonography, Computerized scanning, magnetic resonance imaging and arteriography, which are expensive are required in revision cases only. There are two schools of thought regarding surgical approach. Unilateral neck exploration with preoperative localization as in our case minimizes risk of recurrent laryngeal nerve injury and postoperative hypocalcemia due to loss of vascularity to the normal parathyroid. Bilateral thorough neck exploration (including superior mediastinum and posteriorly upto prevertebral fascia) by an experienced surgeon even without preoperative localization increases cure at initial surgery. Variability in site and number of glands occurs in 20% cases. Gilmour¹¹ found 4 glands in 80%, 3 glands in 13% and 5 in 6% cases. Wang¹² noted aberrant parathyroid in

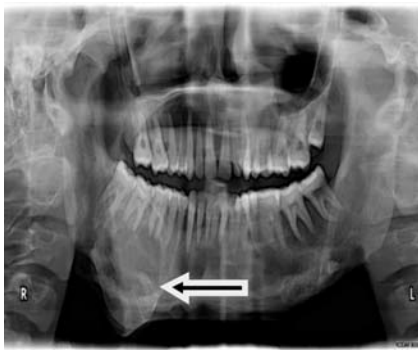


Figure 1. Orthopantomogram showing multilocular radiolucent lesion (arrow) present in right side of mandible involving body. Typical loss of lamina dura was not very evident.

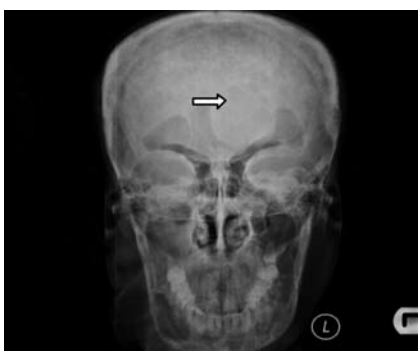

Figure 2. X-ray skull anterior/posterior view showing osteolytic lesion in left frontal region (arrow).

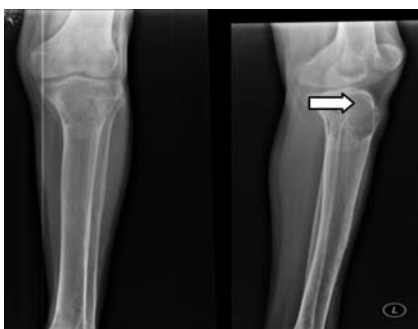

Figure 3. X-ray left knee joint anterior/posterior and lateral view showing osteolytic lesion (arrow).

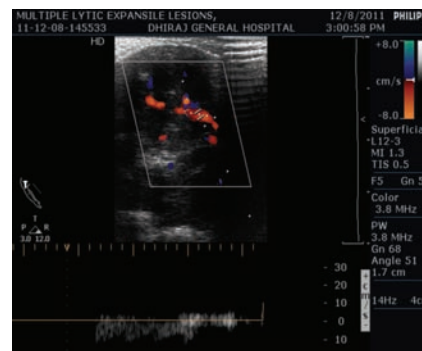


Figure 4. Ultrasonography colored Doppler of neck shows presence of hypo echoic lesion at inferior pole of left thyroid gland.

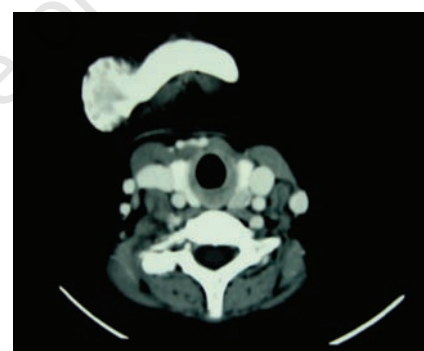


Figure 5. Computerized scan neck (axial view) showing (white arrow) parathyroid adenoma on left side posterior to thyroid gland.

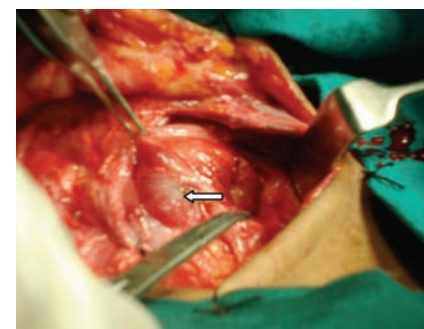


Figure 6. Arrow showing parathyroid adenoma stained blue with methylene blue seen on posterior aspect of left lobe of thyroid (pulled anteriorly).

mediastinum in 18% cases. However the most common ectopic site was retroesophageal in the neck.¹²

Lastly it imperative to remember about the often forgotten fourth cation – magnesium; levels of which may also be deranged following parathyroid surgery aggravating the usual hypocalcaemia.¹³

Conclusions

The presence of underlying primary hyperparathyroidism should be considered in the differential diagnosis of all unexplained multiple lytic lesions involving the jaw and head bones besides the more common group of fibroosseous lesions and occasionally the metastatic lesion.

References

1. Bringhurst FR, Demay MB, Kronenberg HM. Hormones and disorders of mineral metabolism. In: Wilson J, Foster D, Kronenberg H, Larsen P, Eds. Williams textbook of endocrinology. 9th ed. Philadelphia: WB Saunders;1998. pp. 1155-1209.
2. Keyser JS, Postma GN. Brown tumor of the mandible. *Am J Otolaryngol* 1996;17:407-10.
3. Treglia G, Dambra DP, Bruno I, et al. Costal brown tumor detected by dual-phase parathyroid imaging and SPECT-CT in primary hyperparathyroidism. *Clin Nucl Med* 2008;33:193-5.
4. Araújo SM, Bruin VM, Nunes AS, et al. Multiple brown tumours causing spinal cord compression in association with secondary hyperparathyroidism. *Int Urol Nephrol* 2012 Jan 17. [Epub ahead of print].
5. Cebesoy O, Karakok M, Arpacioğlu O, Baltacı ET. Brown tumor with atypical localization in normocalcemic patients. *Arch Orthop Trauma Surg* 2007;127:577-80.
6. Mosekilde L. Primary hyperparathyroidism and the skeleton. *Clin Endocrinol (Oxf)* 2008;69:1-19.
7. Quick CA, Anderson R, Stool S. Giant cell tumors of the maxilla in children. *Laryngoscope* 1980;90:784-91.
8. Nomura R, Sugimoto T, Tsukamoto T, et al. Marked and sustained increase in bone mineral density after parathyroidectomy in patients with primary hyperparathyroidism; a six-year longitudinal study with or without parathyroidectomy in a Japanese population. *Clin Endocrinol (Oxf)* 2004;60:335-42.
9. Melton LJ 3rd. Epidemiology of primary hyperparathyroidism. *J Bone Miner Res* 1991;6 Suppl 2:S25-30.
10. Doppmann JL, Miller DL. Localization of parathyroid tumours in patients with hyperparathyroidism and no previous surgery. *J Bone Miner Res* 1991;6 Suppl 2:S153-8.
11. Gilmour JR. The embryology of the parathyroid glands, the thymus and certain associated rudiments. *J Pathol Bacteriol* 1937;45:507-22.
12. Wang CA. Parathyroid re-exploration. A clinical and pathological study of 112 cases. *Ann Surg* 1997;186:140-5.
13. Wilson RB, Erskine C, Crowe PJ. Hypomagnesemia and hypocalcaemia after thyroidectomy: a prospective study. *World J Surg* 2000;24:722-6.