

# Synchronous ovarian carcinoma with colorectal metastases: an unusual presentation

Kafil Akhtar,<sup>1</sup> Rana Sherwani,<sup>1</sup>  
Afzaal Anees<sup>2</sup>

Departments of <sup>1</sup>Pathology and <sup>2</sup>Surgery,  
Jawaharlal Nehru Medical College,  
Aligarh Muslim University, Aligarh (U.P),  
India

## Abstract

This report describes the case of a 50-year-old female patient who presented with bilateral adnexal lump and dysfunctional uterine bleeding with altered bowel habits. Computed tomography of the abdomen and pelvis revealed a bilateral adnexal lump situated in both the ovaries and a lobular mass of 8 cm in the rectum. Proctoscopy revealed an elevated irregular rectal lesion. The microscopic examination of the ovarian lump revealed a bilateral serous adenocarcinoma with a papillary pattern with psammomatous calcification. A left hemicolectomy with lymphadenectomy was also performed. Immunohistochemical staining was positive for cytokeratin 7 and negative for cytokeratin 20. The use of immunohistochemistry demonstrated the tumor to be of ovarian origin. We report this case of synchronous involvement of the ovary and the colorectum because of its rarity and unusual presentation.

## Introduction

Epithelial cancers represent 90.0% of all malignant ovarian tumors.<sup>1</sup> Primary ovarian cancers tend to spread, at first, within the peritoneal cavity and the omentum, and are frequently associated with ascites, a fluid rich in growth factors and tumor cells disseminated from the primary cancer that fills the peritoneum. Tumor spread to more distant sites, including the contralateral ovary and bilateral ovarian cancers almost always represents a primary tumor and its metastasis rather than dual primary cancers.<sup>2,3</sup> The parallel evolution model suggests that cells with metastatic potential separate from the primary tumor at an early stage in development and evolve independently from the primary tumor.<sup>1</sup>

The ovary is a site for a wide range of tumors, both primary and metastatic. Colorectal metastasis from primary ovarian carcinoma account for approximately 4.0% and an isolated rectal metastasis is very rare.<sup>4,5</sup>

Morphologically, these tumors mimic primary ovarian adenocarcinomas, especially ovarian endometrioid adenocarcinomas. Identification of the correct primary tumor is necessary for an optimal management, including, specific chemotherapy (CT) in advanced stages. Whereas, ovarian adenocarcinomas respond to platinum based CT, cases of colonic adenocarcinomas are candidates for 5-fluorouracil based CT.<sup>6</sup>

## Case Report

A 50-year-old female patient presented with bilateral adnexal lump and dysfunctional uterine bleeding with altered bowel habits. Computed tomography of the abdomen and pelvis revealed a bilateral adnexal lump situated in the ovaries of sizes 10×8 cm and 4×3 cm, and a lobular mass of 8 cm at the rectum with peritoneal implants (Figure 1). Proctoscopy showed an elevated irregular lesion with erosions in the rectum. She underwent a total hysterectomy, a bilateral adnexectomy, and a bilateral iliac lymphadenectomy for the bilateral ovarian lumps. Gross features of the ovaries showed capsular breach with presence of solid and cystic areas on cut sections. The microscopic examination revealed a bilateral papillary serous adenocarcinoma with psammomatous calcification (Figure 2). Iliac lymph nodes were positive for tumor cells. The patient also underwent a left hemicolectomy with lymphadenectomy. Biopsy of the lesion showed moderately differentiated adenocarcinoma (Figure 3). The surgical findings revealed an 8.0 cm submucosal tumor in the rectum and invasion from the serosal side. The tumor primarily involved the rectal muscularis propria and subserosa with only focal invasion of the rectal mucosa. The regional lymph nodes were free of any tumors. Peritoneal dissemination was found to be present which corroborated with the computed tomographic findings. The pathological findings of the ovarian tumor specimen were consistent with those of the hemicolectomy specimen. The patient was staged as T3cN1M1 and stage IV, according to TNM and FIGO classification respectively.

Immunohistochemical staining was positive for cytokeratin 7 (Figure 4) and negative for cytokeratin 20 (Figure 5). This staining pattern was consistent with that of colorectal metastasis from the original ovarian lesion and immunohistochemistry supported the histological interpretation of a metastatic ovarian carcinoma. Post adjuvant 6 cycles of specific CT in the form of cisplatin (50 mg) and 5-fluorouracil (100 mg) were administered to our patient and after 6 months of follow up period, she is doing well.

Correspondence: Kafil Akhtar, Department of Pathology, Jawaharlal Nehru Medical College, Aligarh Muslim University, Aligarh.(U.P)-India. E-mail: drkafilakhtar@gmail.com

Key words: ovarian cancer, colorectal metastasis, immunohistochemistry.

Conflict of interests: the authors declare no potential conflict of interests.

Received for publication: 18 January 2012.

Revision received: 3 March 2012.

Accepted for publication: 2 April 2012.

This work is licensed under a Creative Commons Attribution NonCommercial 3.0 License (CC BY-NC 3.0).

©Copyright K. Akhtar et al., 2012  
Licensee PAGEPress, Italy  
Clinics and Practice 2012; 2:e53  
doi:10.4081/cp.2012.e53

## Discussion

Haraoka *et al.*<sup>5</sup> in an autopsy series, reported that colorectal metastases present with an ovarian origin in about 6.0% of cases and represent about 30.5% of all ovarian cancers. Colorectal metastasis from ovarian cancer is very rare. Koyama *et al.*<sup>7</sup> have reviewed and reported only 19 such cases since 2005 in Japan. Their patients ranged in age from 34 to 77 years with an average age of 58.8 years. The location was ascending colon in 4 patients, transverse in 2, descending in 5, sigmoid in 5, and rectum in 5. The tumor appearance was protruding in 13 cases, ulcerative in 2, and a submucosal tumor type in 1 of the 14 cases in which the macroscopic appearance was reported. In 9 of the 14 cases in which the tumor protruded, the vertex of the tumor was ulcerated.<sup>7</sup> Therefore, distinguishing colorectal metastasis from ovarian carcinoma and primary colon cancer based on the macroscopic appearance is often difficult.<sup>7</sup>

Colorectal metastasis was observed to be synchronous with ovarian carcinoma in 7 patients in a study by Loy *et al.*,<sup>8</sup> a finding similar to our report. In some cases, elevated levels of tumor markers such as CA-125 and CEA may help to make a correct diagnosis. However, up to 15% of the cases of ovarian carcinoma were present without any elevated levels of serum CA-125.<sup>9</sup> Immunohistological staining is very useful to differentiate the origin. Loy *et al.*<sup>8</sup> reported a cytokeratin 7 positive/cytokeratin 20 negative immunophenotype to be nearly 100% specific for an ovarian origin. Conversely, a cytokeratin 7 negative/cytokeratin 20 positive immunophenotype was seen in 94% of the tumors of colonic origin.<sup>10</sup>

In our case, the colonic tumor was positive for cytokeratin 7 and negative for cytokeratin 20, a pattern consistent with an ovarian origin rather than a colonic one. In addition, a comparison of the patient's primary ovarian cancer with the colorectal mass revealed that the two tumors have similar histological features.

The spread of ovarian cancer to the colorectum can occur in four different ways, hematogenous spread, lymphatic spread, direct invasion and peritoneal dissemination.<sup>3</sup> The

most plausible explanation of colorectal involvement in ovarian adenocarcinomas is through intra-peritoneal seeding. Hematogenous spread occurs in advanced peritoneal disease. In a substantial number of autopsy cases of advanced ovarian cancers, Reed *et al.*<sup>11</sup> identified peritoneal involvement in 83-100% cases, with large intestinal involvement in 50-60% cases. In most cases of bowel metastases, the serosa is affected initially and then invasion extends from serosal and subserosal tissues into the muscularis propria and mucosa of the bowel wall.<sup>12</sup> In the present case, the tumor mainly involved the rectal muscularis propria and subserosa with only focal invasion of the rectal mucosa and invasion of the retroperitoneum. The pattern of metastasis was thought to have spread by the peritoneal route.

Certain morphological features indicative of metastasis from colorectum include *garland-like* tumor necrosis, segmental destruction of glands and absence of squamous metaplasia, whereas cribriform growth patterns and intraluminal *dirty* necrosis are indicators of ovarian adenocarcinomas.<sup>10</sup> However, the problem exists in sorting out these tumors, including in cases mucinous adenocarcinomas, when there

is simultaneous involvement of the ovary and the colorectum at similar (synchronous) or at different (metachronous) times.<sup>2</sup> Rekhi *et al.*<sup>12</sup> showed that morphologically, metastatic tumor deposits in the colorectum retained the morphology of ovarian papillary serous cystadenocarcinoma with foci of psammomatous calcification in 6 of their 11 cases. Absence of *garland-like* tumor and necrosis were pointers towards an ovarian primary, apart from the clinical context of a preceding ovarian tumor in 81.8% such cases.<sup>13</sup> It is thus important to identify whether or not a tumor has an ovarian origin using immunohistochemical markers, since the occurrence of gastrointestinal metastases from ovarian cancer is very rare. As described lately, specific cytokeratin immunomarkers like cytokeratin 7 and cytokeratin 20 have been documented to be helpful in resolving these dilemmatic situations of ovarian involvement by colorectal carcinoma and vice versa. Zigelboim *et al.*<sup>13</sup> described a single case of atypical sigmoid metastasis from a high-grade ovarian adenocarcinoma, using differential expression of CK7 and 20.

O'Hanlan *et al.*<sup>14</sup> have reported that a longitudinal negative margin of 2-5 cm in the resected bowel along with a wedge resection of mesentery, including paracolic and intermediate-level nodes might be indicated to achieve optimal debulking of gastrointestinal metastases from ovarian carcinomas. Our patient underwent total hysterectomy, bilateral adnexectomy, and bilateral iliac lymphadenectomy with left hemicolectomy and postoperative chemotherapy.

## Conclusions

In cases of colorectal involvement by ovarian adenocarcinomas and vice versa, it can be difficult to ascertain an exact primary. In such cases, apart from complete clinical details, histomorphological features like *garland-like* necrosis, desmoplasia and psammomatous calcification are useful pointers towards exact primary and along with differential expression of cytokeratins 7 and 20 by immunohistochemistry can be helpful in solving these dilemmas.

## References

1. Nakamura Y, Kaneda K, Wada T. A case of rectal metastasis 22 years after removal of ovarian cancer. *J Jpn Surg Assoc* 2006;67: 2142-6.
2. Shibahara K, Endo K, Ikeda T, et al. Colon metastasis 20 years after the removal of ovarian cancer: report of a case. *Surg Today* 2009;39:153-6.

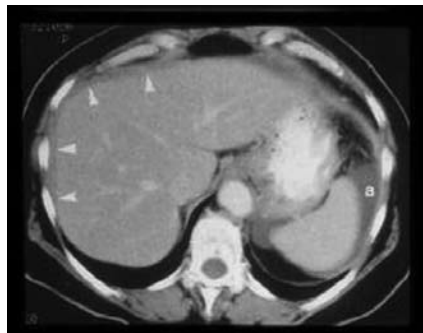

Figure 1. Computed tomography of the abdomen revealed a bilateral adnexal lump situated in both the ovaries with peritoneal implants.

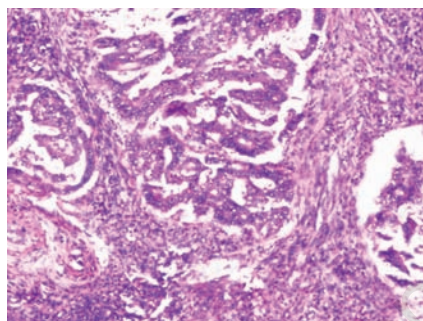


Figure 2. Carcinoma Ovary shows papillary serous adenocarcinoma with psammomatous calcification (Hematoxylin & Eosin x40).

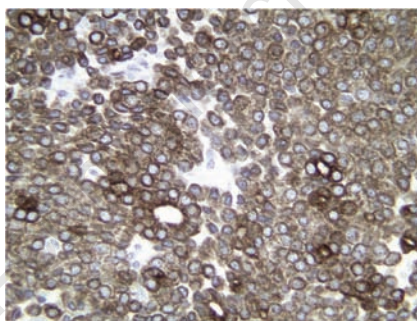


Figure 4. Positive immunohistochemical staining for cytokeratin 7 (Immunostain Cytokeratin 7 x 40).

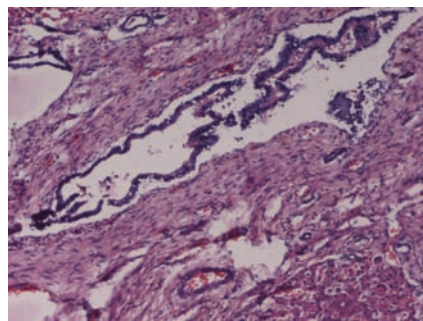


Figure 3. Colorectal carcinoma shows moderately differentiated adenocarcinoma (Hematoxylin & Eosin x40).

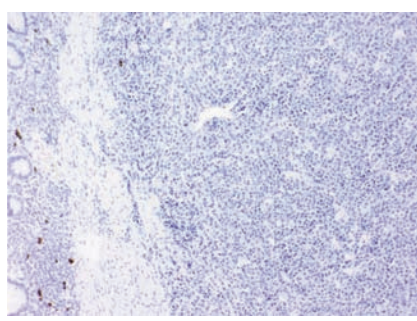


Figure 5. Negative immunohistochemical staining for cytokeratin 20 (Immunostain Cytokeratin 20 x 40).

3. Tei S, Murata T, Sibuya M, et al. A case of colon metastasis of ovarian cancer. *J Jpn Surg Assoc* 2005;66:886-8.
4. Nakao Y, Suzumura K, Nagata H, et al. A case of colon metastasis of ovarian cancer. *J Chubu Surg Soc* 2005;41:92.
5. Haraoka S, Iwashota A, Nakayama Y. Metastatic tumor of the gastrointestinal tract. *Stomach Intestine* 2003;38:1755-71.
6. Sobrero AF, Aschele C, Bertino JR. Fluorouracil in colorectal cancer – a tale of two drugs: implications for biochemical modulation. *J Clin Oncol* 1997;15:368-81.
7. Kohyama M, Takesue Y, Ohge H, et al. A case of colon metastasis from ovarian cancer presented with intussusception. *J Jpn Surg Assoc* 2005;66:2767-71.
8. Loy TS, Calaluce RD, Keeney GL. Cytokeratin immunostaining in differentiating primary ovarian carcinoma from metastatic colonic adenocarcinoma. *Mod Pathol* 1996;9:1040-4.
9. Takahashi K, Shibukawa T, Moriyama M, et al. Clinical usefulness and false-positive results of CA 125 as a tumor marker of ovarian cancer: a study on 674 patients. *Jpn J Surg* 1986;16:305-10.
10. Lindner V, Gasser B, Debbiche A, et al. [Ovarian metastasis of colorectal adenocarcinomas. A clinicopathological study of 41 cases]. *Ann Pathol* 1999;19:492-8. [Article in French].
11. Reed E, Zerbe CS, Brawley OW, et al. Analysis of autopsy evaluations of ovarian cancer patients treated at the National Cancer Institute, 1972-1988. *Am J Clin Oncol* 2000;23:107-16.
12. Rekhi B, George S, Madur B, et al. Clinicopathological features and the value of differential cytokeratin 7 and 20 expression in resolving diagnostic dilemmas of ovarian involvement by colorectal adenocarcinoma and vice-versa. *Diagn Pathol* 2008;3:39.
13. Zigelboim I, Broaddus R, Ramirez PT. Atypical sigmoid metastasis from a high-grade mixed adenocarcinoma of the ovary. *Gynaecol Oncol* 2004;94:850-3.
14. O'Hanlan KA, Kargas S, Schreiber M, et al. Ovarian carcinoma metastases to gastrointestinal tract appear to spread like colon carcinoma: implications for surgical resection. *Gynecol Oncol* 1995;59:200-6.

Non-commercial use only